

ANATOMY OF THE MUSCLE (structure and type)

Subject: Human Biology

dr. Santosa Budiharjo, MKes., PA(K)

Department of Anatomy. School of Medicine

Faculty of Medicine, Public Health and Nursing UGM

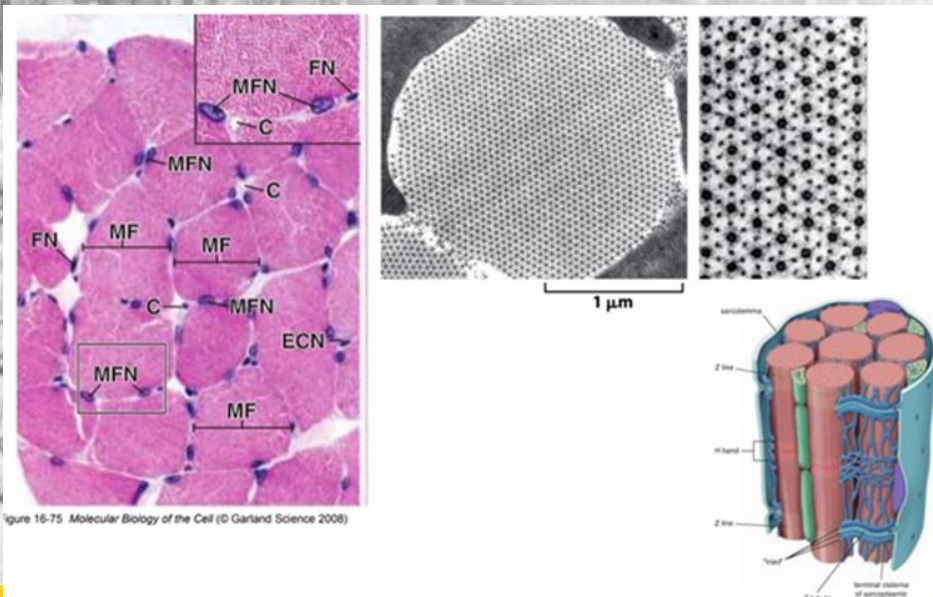
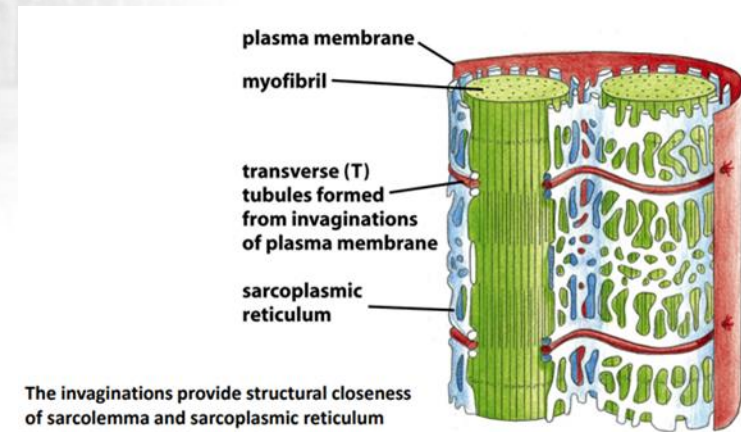


Figure 16-75 Molecular Biology of the Cell (© Garland Science 2008)



The invaginations provide structural closeness of sarcolemma and sarcoplasmic reticulum

16-77a Molecular Biology of the Cell (© Garland Science 2008)


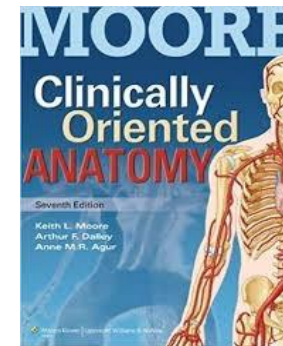




LO, to understand:

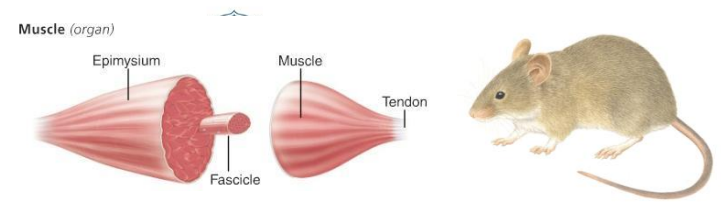
1. Terminology and Definition of muscular system
2. Type of muscle and muscle function
3. Structural unit, motor unit and innervation of muscle
4. Muscle fiber orientation
5. How are muscle named

REFERENCES

1. Gray`s Anatomy
2. Moore Clinical Oriented Anatomy
3. Prometheus, Atlas Anatomi Umum dan Sistem Gerak
4. etc



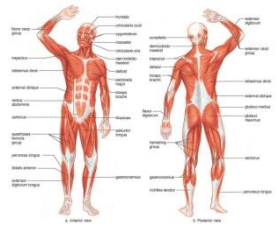
LO 1 : TERMINOLOGY AND DEFINITION OF MUSCULAR SYSTEM



Macroanatomy : gross anatomy, visible level, macroscopic

Muscle in Latin Musculus (little mouse), **Ancient Greek**: Mussel.

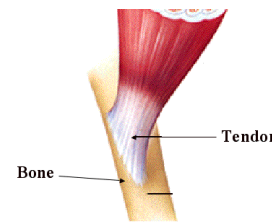
Muscle tissue is a bundle of long slender cells (muscle fibers) that can produce movement, has physiologic characteristics: excitable or irritable, contractible, extensible, elasticity and adaptable.



Muscle is as an organ make up the muscular system of the body to serve a movement. Muscle as an organ has unique and specific shape.

Muscular system is composed skeletal muscles, smooth muscle in visceral organs, cardiac muscle and accessories organ of muscle to serve body movement.

ACCESSORIES ORGAN OF MUSCLE

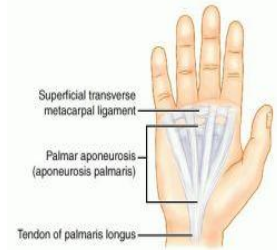

A tendon

- is a cord or band of white in elastic collagenous tissue that attaches a muscle to a bone or some other part.

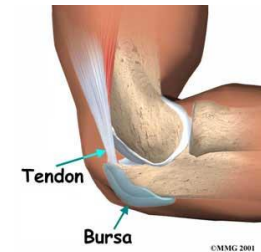Aponeurosis:

A sheetlike fibrous membrane, resembling a flattened tendon, as a means of connecting muscle to bone



Synovial bursae sheath:

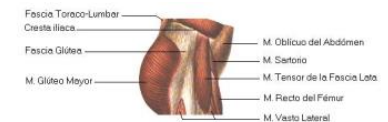
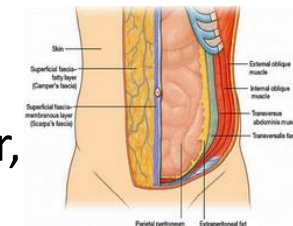
a pouch, a sac containing synovia, to facilitate motion, as between a tendon and a bone



Fascia:

is a structure of connective tissue that surrounds muscles, groups of muscles, blood vessels, and nerves, binding some structures together, while permitting others to slide smoothly over each other.

There are two type of fascia: superficial and profundal fascia



SKELETAL MUSCLE PARTS

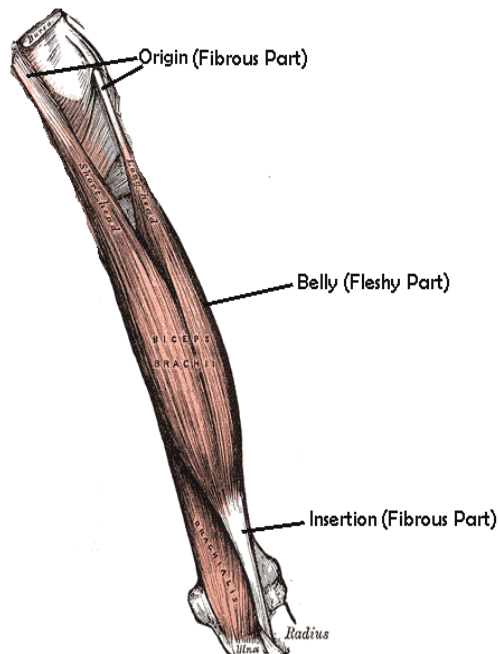
There are 3 parts,

1. Caput

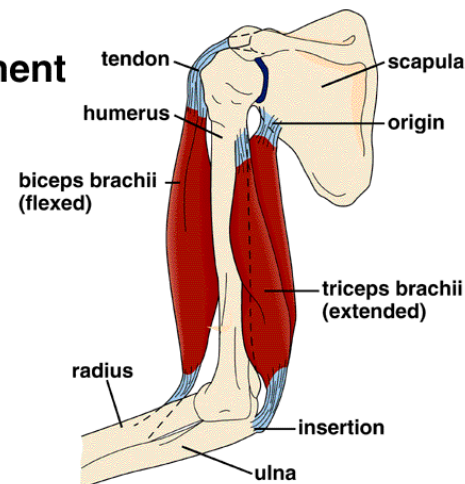
proximal parts, close to the punctum fixum (origo)

2. Venter (middle part, belly)

3. Cauda, Tendo (connect to the bone as mobile parts (insertion) or fixum part (origo))



Muscle Attachment



LO 2: Type of muscle and Muscle function



Type of muscle based on contraction activity and microscopic description

1. Skeletal muscle

Action voluntary, conscious, strong, quick, discontinuous, striated, non-branched, multinucleus

2. Smooth muscle

Action involuntary, un-conscious, non-striated, weak, slow, tapered, single nucleus

3. Cardiac muscle (wall of heart)

Action involuntary, striated muscle with intercalated disk (branched), strong, quick, continuous, single nucleus

Muscle types


Skeletal muscle



Cardiac muscle



Smooth muscle



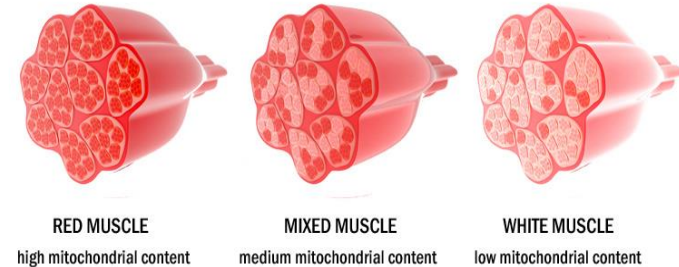

Skeletal Muscle	Cardiac Muscle	Smooth Muscle
1. Striated.	1. Striated.	1. Nonstriated.
2. No syncytium.	2. Syncytial.	2. Syncytial.
3. Small T tubules.	3. Large T tubules.	3. Generally rudimentary T tubules.
4. Sarcoplasmic reticulum well-developed and Ca^{2+} pump acts rapidly.	4. Sarcoplasmic reticulum present and Ca^{2+} pump acts relatively rapidly.	4. Sarcoplasmic reticulum often rudimentary and Ca^{2+} pump acts slowly.
5. Plasmalemma lacks many hormone receptors.	5. Plasmalemma contains a variety of receptors (eg, α - and β -adrenergic).	5. Plasmalemma contains a variety of receptors (eg, α - and β -adrenergic).
6. Nerve impulse initiates contraction.	6. Has intrinsic rhythmicity.	6. Contraction initiated by nerve impulses, hormones, etc.
7. Extracellular fluid Ca^{2+} not important for contraction.	7. Extracellular fluid Ca^{2+} important for contraction.	7. Extracellular fluid Ca^{2+} important for contraction.
8. Troponin system present.	8. Troponin system present.	8. Lacks troponin system; uses regulatory head of myosin.
9. Caldesmon not involved.	9. Caldesmon not involved.	9. Caldesmon is important regulatory protein.
10. Very rapid cycling of the cross-bridges.	10. Relatively rapid cycling of the cross-bridges.	10. Slow cycling of the cross-bridges permits slow prolonged contraction and less utilization of ATP.

Harper's Illustrated Biochemistry



Type of muscle Based on: mitochondrial content



1. Red muscle

High mitochondrial content, dark red
slow contraction, slow oxidative, aerobic respiration, marathon runner,
type I muscle fiber, small muscle fiber, slow-twitch fiber

2. White muscle

Low mitochondrial content
fast contraction, fast glycolytic, sprinter, type II muscle fiber, larger
muscle fiber, fast-twitch fiber



3. Mix muscle

Medium mitochondrial content, red to pink
fast contraction, fast oxydative, muscle fiber intermediate in size



TYPE OF MUSCLE FIBER

Type 1 : red muscle

High in oxidative activity, low in glycolytic activity and are red grossly because of a high content of myoglobin and mitochondrial cytochromes.

They contract slowly, but are capable of repeated or continuous contraction

Type 2: white muscle

Low in oxidative activity and high in glycolytic activity. They are white grossly and are capable of rapid contraction, but cannot maintain repeated contraction indefinitely

A majority of long distance endurance athletes are born with an exceptional amount of Slow Red Fibers.

In contrast, strength athletes such as wrestlers and bodybuilders usually have a higher amount of Fast White Fibers.

CHARACTERISTIC	TYPE 1	TYPE 2
Contraction	Slow	Fast
Color	Red	White
Oxidation	High	Low
Glycolysis	Low	High
Myoglobin Mitochondria	Abundant	Sparse
ATPase, pH 9.4	Light	Dark
Glycogen	Scant	Abundant
Repeated or continuous contraction	Capable	Can not

ONE SLOW RED OX

Endurance athletes

TWO FAST WHITE SUGAR

Body builder

12

MNEMONICS

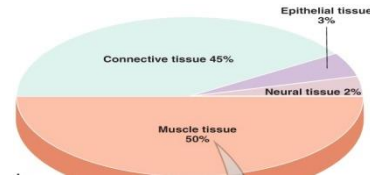


Differences In Skeletal Muscle Fiber Types

	Type I fibers	Type II a fibers	Type II x fibers	Type II b fibers
Contraction time	Slow	Moderately Fast	Fast	Very fast
Resistance to fatigue	High	Fairly high	Moderate	Low
Activity Used for	Aerobic activity	Long-term anaerobic activity	Short-term anaerobic activity	Short-term anaerobic activity
Maximum duration of use	Hours	Less than 30 minutes	Less than 5 minutes	Less than 1 minute
Power produced	Low	Medium	High	Very high
Mitochondrial density	Very High	High	Medium	Low
Capillary density	High	Intermediate	Low	Low
Oxidative capacity	High	High	Moderate	Low
Major storage fuel	Triglycerides	Creatine phosphate, glycogen	ATP, Creatine phosphate, glycogen (little)	ATP, Creatine phosphate
Properties	Consumes lactic acid	Produce lactic acid and Creatine phosphate	Consume Creatine phosphate	Consume Creatine phosphate



MUSCLE FUNCTIONS



- 1. Body movement (body parts) maintain posture /motion (move to anywhere) (skeletal muscle) the (driving force)**
- 2. Body heat (skeletal muscle)**
- 3. Body shape (skeletal muscle) (around 50% body composition)**
- 4. Circulation: Blood circulation, lymph circulation (cardiac muscle, smooth muscle, skeletal muscle)**
- 5. Food digestion (smooth muscle)**
- 6. Micturion, defecation, breathing inhale, baby delivery (parturition) (smooth and skeletal muscle)**



LO 3: organization of muscle fibers structural & motor unit, innervation

Organization of muscle fiber

A MUSCLE, surrounded by epimysium

is made of bundles of FASCICLE

ONE FASCICULUS, surrounded by perimysium

- is made of muscle FIBERS

ONE MUSCLE FIBER (MYOFIBER), surrounded by endomysium

- is a MUSCLE CELL, that contains MYOFIBRILS

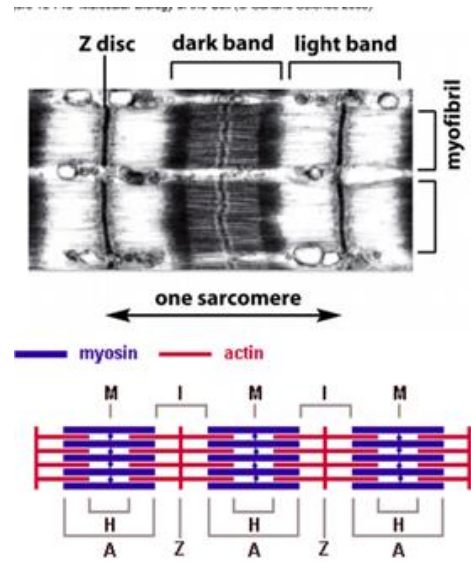
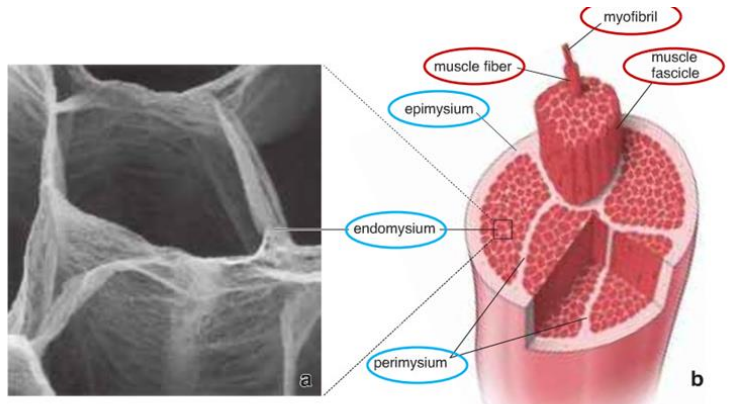
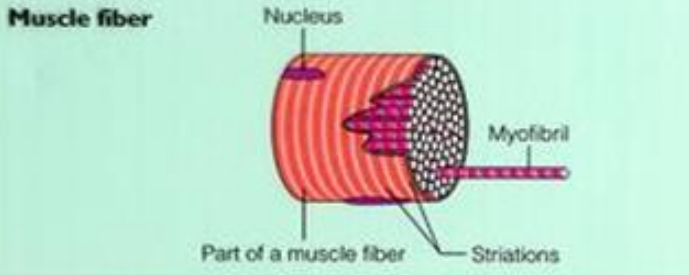
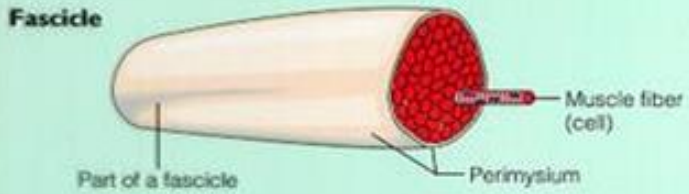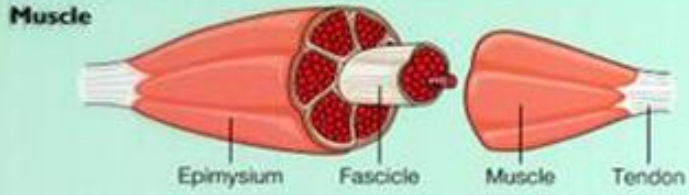
A MYOFIBRIL is composed of bundles of MYOFILAMENTS

ONE MYOFILAMENT contains contractile proteins (actin & myosin); (Seen only on Electron Microscope). The filaments arranged regularly as structural unit is called SARCOMERE)



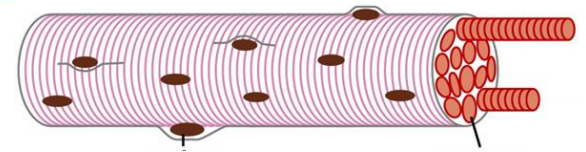
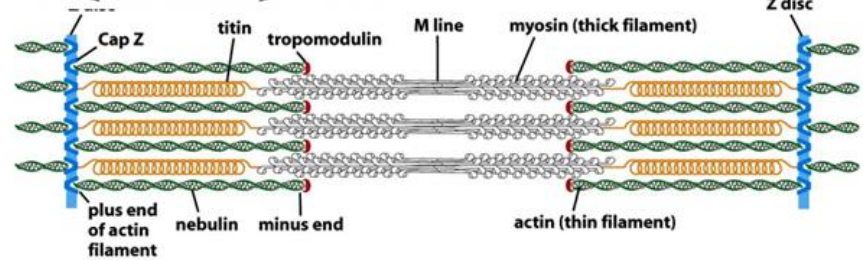
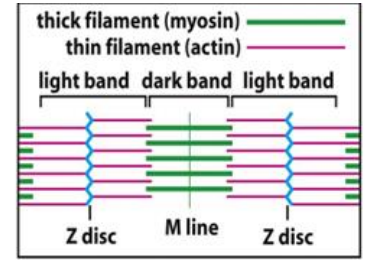
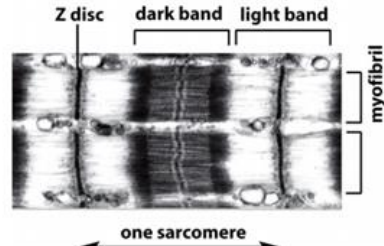
UNIVERSITAS
GADJAH MADA

Structure and organizational level



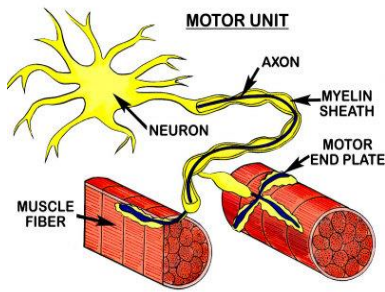
Bands and lines in the contractile apparatus of skeletal muscle

Figure 16-74b Molecular Biology of the Cell (© Garland Science 2008)



- Light (I)-band
 - actin filaments
- Dark (A)-band
 - myosin filaments which may overlap with actin filaments,
- H-band
 - zone of myosin filaments only (no overlap with actin filaments) within the A-band
- Z-line
 - zone of apposition of actin filaments belonging to two neighbouring sarcomeres (mediated by a protein called alpha-actinin),
- M-line
 - band of connections between myosin filaments (mediated by proteins, e.g. myomesin, M-protein).

Each muscle fascicle consists of several muscle fibers (skeletal muscle cells)



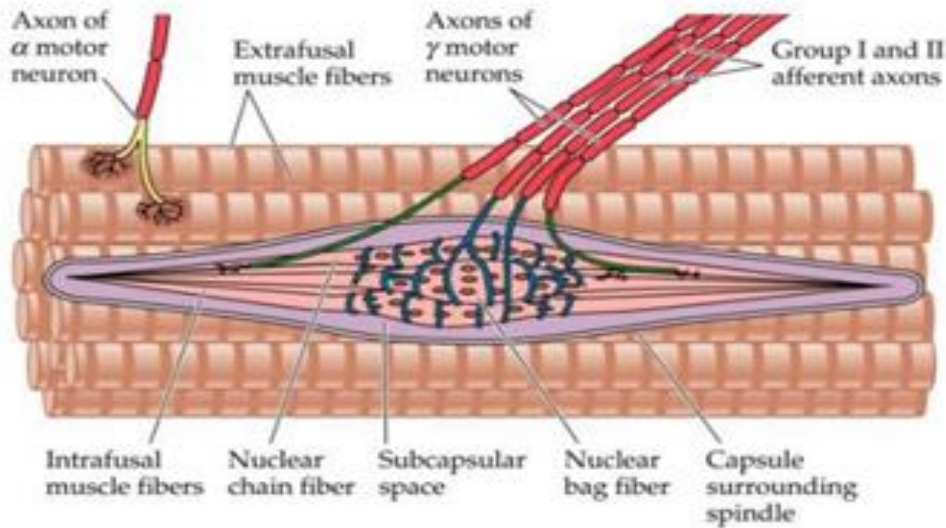
A motor unit (innervation of muscle fiber)

	Ocular	Skeletal
Fiber diameter	9–17 μm	90–100 μm (gluteus maximus)
Ratio of nerve to muscle fiber	1:1–17	Up to 1:300
Contraction time	Fast	Slow
Acetylcholine sensitivity	High	Low or absent

- **is made up** of a motor neuron and the skeletal muscle fibers innervated by that motor neuron's axonal terminals
- **Motor neuron with large size** cause a fast contraction in the larger muscle fibers so that the fibers are called the fast type but are easily fatigued.
- **The small motor neurons**, with a slow contraction time (the fibers are called the slow type, and do not get tired quickly).
- **Ratio of nerve to muscle fiber** depend the complexity function of movement

The group of muscle fibers innervated by all of the collateral branches or the axon from one motor neuron

Small- fine movements/small force; large – coarse movements/large force



Extrafusal muscle fibers and intrafusal muscle fibers innervation

- **Extrafusal muscle fibers (skeletal muscle fiber)** are muscle fibers innervated by alpha motor neurons, and in them there are sarcomere sequences
- **Intrafusal (fusimotor) muscle fibers** are muscle fibers found in muscle spindles, the motor intrafusal muscle fibers innervate by gamma motor neuron.
- Muscle fibers in the **muscle spindle** or “**fusus**” (Latin), in the belly of muscle, as a stretching sensor, detection of muscle extension, and at the ends of the spindles have motor innervation from gamma motor neurons. Intrafusal fibers contractions cause the spindle taut, and detect the lengthen of muscle.
- **Muscle spindles are sensory devices (proprioceptor)**, to find out stretching of muscle extension, and the information send to central nervous system.



LO 4: Muscle fiber orientation

Two type group of muscle fibers orientation

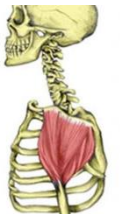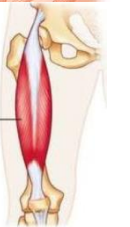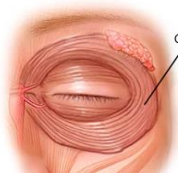
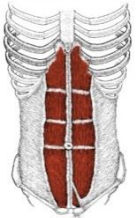
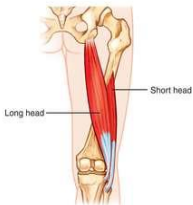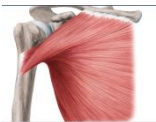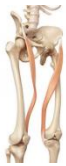1. Parallel (parallel to the length of the muscle), (produces greater range of movement)

divided into: **Flat** (m. rectus abdominis); **Fusiform** (like a spindle, m. brachialis); **Strap** (m. Sartorius); **Radiate/Fan-shape/convergen**(m. pectoralis major); **Sphincter** (circular fibers, m. orbicularis oculi)

2. Pennate (shorter fibers, obliquely to their tendons) (produces greater force)

Divided into: **Unipennate** (one side of tendon) (m. biceps femoris);

Bipennate (both side of tendon in central part) (m. rectus femoris); **Multipennate** (several tendons, the fibers run diagonally in between tendons (m. deltoideus)



LO 5 : How are muscle named?



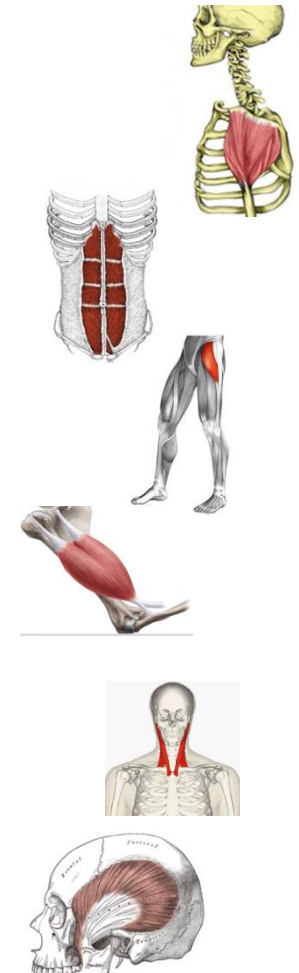Named of muscle can contain one word, two words or more.

Muscle (English), or in Latin. Musculus (singular), musculi (plural).

Abbreviation in latin "M or m. (singular) and Mm. or mm. (plural)

The muscle name refers to:

- **Shape** (e.g.. **m. deltoideus**, delta in Greek looks like triangle)
- **Size** (e.g. **m. vastus medialis** , great, **vastus** in Greek means great)
- **Muscle fiber orientation** (e.g **m. rectus abdominis**. Rectus means straight, run parallel to the midline)
- **Action or function** (e.g. **m. tensor fascia latae**, Tensor is making rigid or tension to the fascia latae)
- **Number parts of muscle** (e.g. **m. biceps brachii**, two heads as origin)
- **Origin and insertion** (e.g. **m. sternocleidomastoideus** origin at part of sternum and clavicle, insertion at the part mastoid bone)
- **Location/position** (e.g. **m. temporalis**, at the temporal region of head)





UNIVERSITAS
GADJAH MADA

**SUCCESS
THANK YOU
SEE YOU!!**

**Don't forget to watch another videos from our Anatomy Department,
Remember this video just a trigger to learn anatomy to be better.**