USG untuk Anestesia Regional

Tujuan

- mengetahui prinsip dasar ultrasonografi untuk anestesia regional
- mengetahui keunggulan dan kelemahan ultrasonografi pada anestesia regional.

Tantangan dalam RA

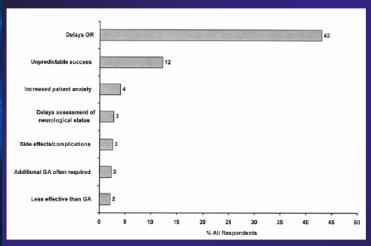

- procedure time
- onset time
- failure rates
- complications

Oldman M, et al. A survey of orthopedic surgeons' attitudes and knowledge regarding regional anesthesia. *Anesth Analg* 2004; 98:1486 –90.

Mengapa USG?

- Metode melokalisasi saraf dgn teknik parestesia dan stimulator saraf = teknik “buta” (blind procedure)
- Pergerakan jarum bisa menimbulkan komplikasi walaupun insidensnya jarang.
- Dgn USG dpt “melihat langsung” anatomi, arah tusukan jarum dan penyebaran obat

Ultrasound dalam RA

- 1978: La Grange pertama kali mempublikasikan penggunaan USG doppler untuk blok supraklavikular

(La Grange et al. Application of the doppler ultrasound flow detector in supraclavikular brachial plexus block. *Br.J Anaesth.* 1978;50:965-5)

Penggunaan lain USG dalam Anestesia

- Akses vaskular
- Ekokardiografi: transtorasik, transesofageal
- Sonografi spinal
- Menilai jalan nafas (mis. pd tumor tiroid yg besar, menilai posisi ETT)
- Diagnostik area dada (mis.hemotoraks, efusi perikardium)
- Klinik Nyeri (mis.identifikasi neuroma, injeksi myofasial trigger point, infiltrasi tumor)

Evidence Based Medicine

Berikut ini merupakan bbrp bukti (evidence) penggunaan USG untuk anestesia regional

Kasus serial infraklavikular (1)

- 60 patients
- injections (15 ml x2) medial and lateral to subclavian artery: "doughnut sign"
  - ✓ 57 (95%) patients without supplements
  - ✓ subclavian a. and v., pleura, lung identified
  - ✓ 3 patients: paresthesia
  - ✓ no other complications

Ootaki C, et al. Ultrasound-guided infraclavicular brachial plexus block: an alternative technique to anatomical landmark-guided approaches. *Reg Anesth Pain Med* 2002;25:600-4.

Kasus serial infraklavikular (2)

- 126 patients
- injection around each cord (total x3), with test injectate (1-2 ml) to assess spread
  - ✓ time to perform block 10 (4.4) min
  - ✓ complete block 6.7 (3.2) min
  - ✓ 114 (90%) patients without GA or supplementation
  - ✓ 53 patients: catheter for continuous block
  - ✓ complications
    - 1 patient: blood aspirated from needle
    - 3 patients: paresthesia

Waktu lebih singkat, dlm 17mnt sudah total blok

Sandhu NS, et al. Ultrasound-guided infraclavicular brachial plexus block. *Br J Anaesth*. 2002; 89:254-259.

RCT blok 3in1

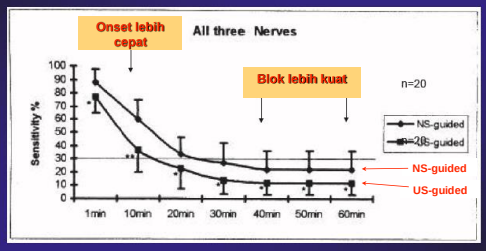

Marhofer P, et al. Ultrasonographic guidance improves sensory block and onset time of three-in-one blocks. *Anaesth Analg* 1997; 85(4):854-7.

RCT blok 3in1

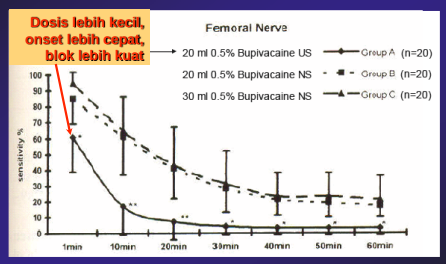

Marhofer P, et al. Ultrasonographic guidance reduces the amount of local anesthetic for 3-in-1 blocks. *Reg Anesth Pain Med* 1998; 23:584-8.

Infraklavikular blok pd anak

- 40 children aged 1-10 yo, arm and forearm surgery for trauma
- sedation with midazolam PR and IV
- infraclavicular brachial plexus block: ultrasound guided or electro-stimulation
- 0.5% ropivacaine 0.5 ml/kg
- all patients had surgical anaesthesia, none required GA

Marhofer P, et al. Ultrasound guidance for infraclavicular brachial plexus anaesthesia in children. *Anaesth*. 2004;59:642–646.

	Group US	Group NS	p
Sensory Onset Time (min)	9 [5 -15]	15 [5 - 25]	< 0.001
Sensory Block Duration (min)	384 [280 - 480]	310 [210 - 420]	< 0.001
VAS during Puncture	3.00 [1 - 4]	3.75 [3 - 5]	< 0.05

Marhofer P, et al. Ultrasound guidance for infraclavicular brachial plexus anaesthesia in children. *Anaesth*. 2004;59:642–646.

Blok ilioinguinal pd anak #1

- 100 children, 1 mo – 8 yo
- under GA: Ilio-inguinal/-hypogastric nerve blocks
- ultrasound guided vs conventional "fascial click"
- 0.25% levobupivacaine
  - ✓ US guided: LA spread around target nerves
  - ✓ fascial click: 0.3 ml/kg

Willschke H, et al. Ultrasonography for ilioinguinal/iliohypogastric nerve blocks in children. *Br J Anaesth*. 2005;95:226-30.

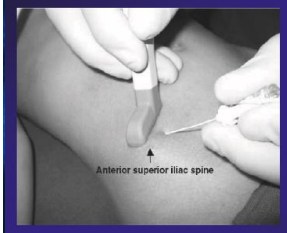

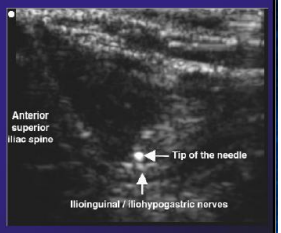

Willschke H, et al. Ultrasonography for ilioinguinal/iliohypogastric nerve blocks in children. *Br J Anaesth*. 2005;95:226-30.

Blok ilioinguinal pd anak #2

	Group "US"	Group "Click"	p
LA Dosage	0.19 ml/kg	0.3 ml/kg	< 0.001
↑ HR at Incision	1 (6) %	13 (22) %	< 0.001
Fentanyl at incision	2 (4%)	13 (26%)	< 0.005
Postop PR Paracetamol	3 (6%)	20 (40%)	< 0.001

Willschke H, et al. Ultrasonography for ilioinguinal/iliohypogastric nerve blocks in children. *Br J Anaesth*. 2005;95:226-30.

Keuntungan teknik USG

- Mengurangi komplikasi RA
- Meningkatkan keberhasilan blok
- Onset lebih cepat
- Dpt mengatasi variasi anatomi pasien
- Mengurangi dosis obat
- Injeksi obat AL dapat diulang tanpa kesulitan mengidentifikasi saraf
- Memudahkan pemasangan kateter

Kelemahan teknik USG

- Alat mahal, transducer khusus
- Portabel ? (trgantung jenis/merk alat)
- Image yg dihasilkan tidak selalu jelas, kadang dgn artefak


Teknik USG pd RA
20

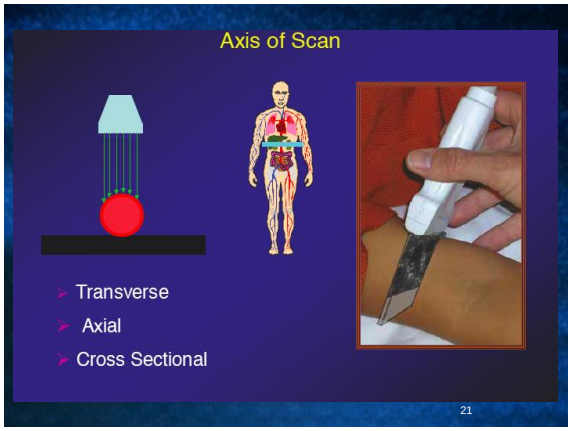
Axis of Scan
Transverse
Axial
Cross Sectional
21

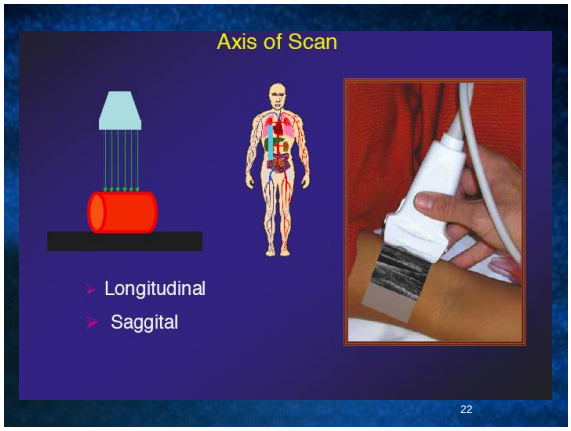
Axis of Scan
Longitudinal
Saggital
22

Axis of Scan

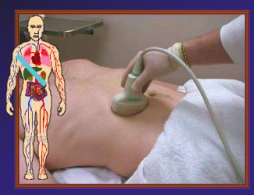

- Oblique
- Coronal

Axis of Intervention

- Short Axis
- SAX
- Out of Plane



Axis of Intervention

- Long Axis
- LAX
- Longitudinal axis
- In Plane

Probe Orientation

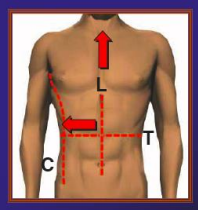

The probe orientation marker should be pointed

- to the patient's right side: transverse scan
- to the patient's head: longitudinal / saggital / coronal scan

Ultrasound Gel

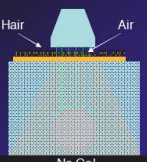

No Gel

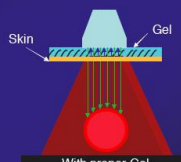

With proper Gel

Echogenecity of Tissue

Isoechoic – Same echogenicity as surrounding tissues.



Hypoechoic – Less echogenic than surrounding tissues. Appears as weaker reflection = grey dots
Most solid organs



Hyperechoic – More echogenic than surrounding tissues. Appears as Strong reflection = white dots.
Diaphragm, gallstones, bone

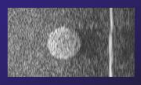

Anechoic – Absence of echos. Appears as black dots. Fluid within a cyst, urine, blood



How do we identify….?

- **Veins** – Anechoic, compressible, non pulsatile
- **Arteries** – Hypoechoic, pulsatile
- **Fat** – Hypoechoic
- **Muscle** –
  - ✓ Perimysium: hyperechoic
  - ✓ Muscle fiber: hypoechoic
- **Nerve** – hyper or hypoechoic
- **Bone** – Hyperechoic / hypoechoic - acoustic shadow
- **Pleura** – hyperechoic
- **Tendon** – Hyperechoic tendon sheath separated from the tendon by a thin hypoechoic area

Anisotropy

Median Nerve in the Forearm – Transverse scan

Brachial Plexus - Interscalene Groove

HFL38 13-6 MHz

High Frequency Linear Probe eg, HFL38 13-6MHz

Brachial Plexus - Interscalene Groove

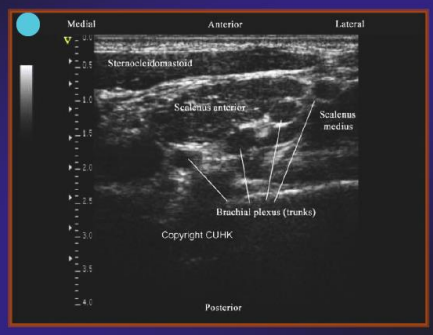

Brachial Plexus - Supraclavicular Fossa

HFL38 13-6 MHz

Probe used: High Frequency Linear Probe

SLA 13-6 MHz

Brachial Plexus – Supraclavicular Fossa

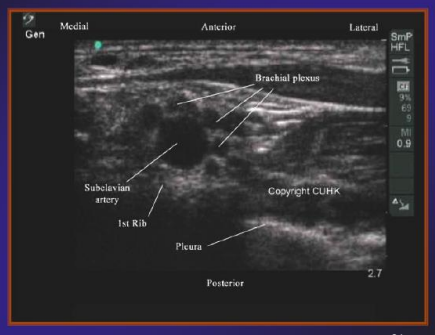

Brachial Plexus - Infraclavicular Fossa

Probe used: Linear Array Probe, L38e 10-5 MHz

Brachial Plexus – Infraclavicular Fossa

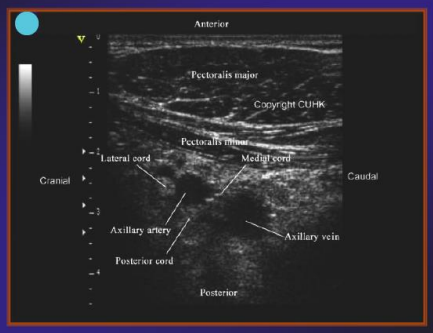

Brachial Plexus - Axilla

HFL38e 13-6 MHz

Probe used: High Frequency Linear Probe

Brachial Plexus – Axilla

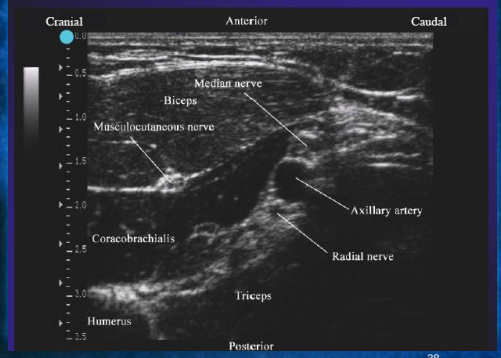

38

Femoral Nerve – Femoral triangle (Transverse scan)

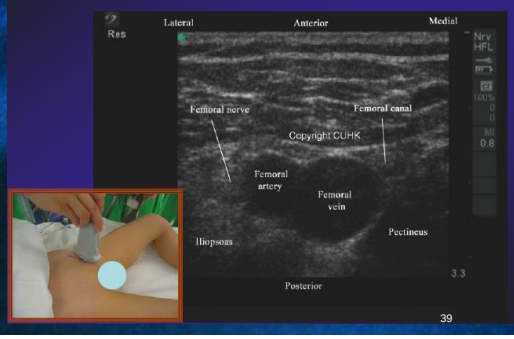

39

Sciatic Nerve – Transgluteal Approach

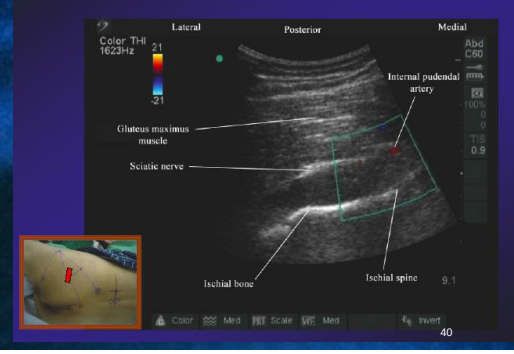

40

Sciatic Nerve – Infratrochanteric Approach

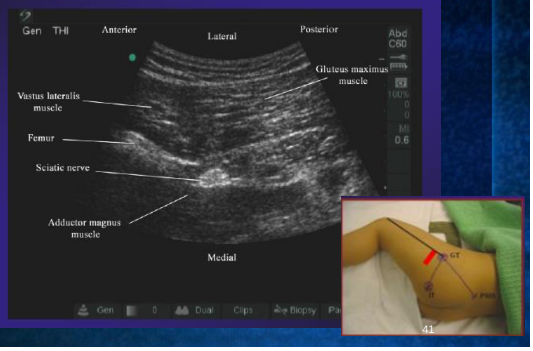

Sciatic Nerve – Apex of Popliteal fossa (Transverse scan)

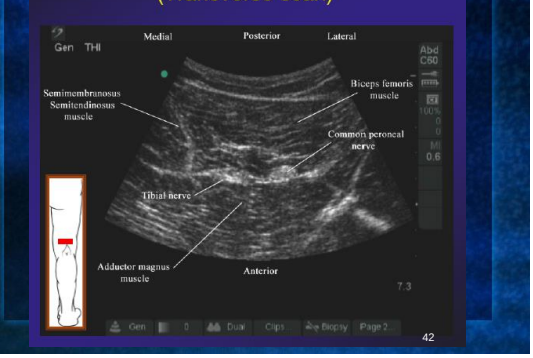

Sciatic Nerve – Mid Thigh Approach (Transverse scan)

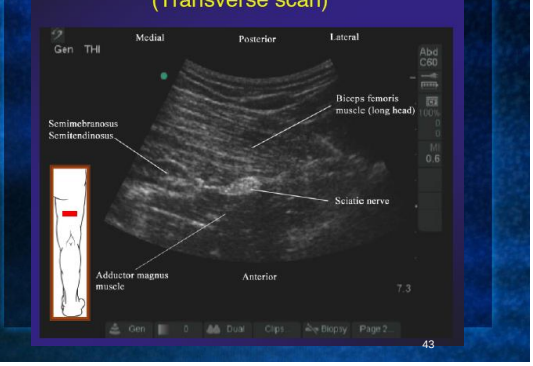

video
blok saraf femoral dipandu usg

TERIMA KASIH

with special thanks to:

Dr. M. K. KARMAKAR
Department of Anesthesia and Intensive Care
The Chinese University of Hong Kong
Prince of Wales Hospital
Shatin
Hong Kong
www.anesweb.com