

Renovascular Hypertension and Ischemic Nephropathy

Vesna D. Garovic, MD; Stephen C. Textor, MD

Major improvements in imaging, medical therapy, and techniques of renal revascularization have changed the landscape of renovascular disease during the past decade. This has been particularly true for atherosclerotic renal artery stenosis, which remains one of the most common conditions known to accelerate hypertension and one of the most common incidentally detected vascular lesions. Despite, or perhaps because of, these developments, few clinical questions provoke more controversy and debate among cardiologists, internists, and nephrologists than decisions about the optimal management of patients with main renal artery stenosis.

Even well-informed clinicians from different subspecialties hold widely divergent opinions about the role of renal revascularization, particularly for atherosclerotic disease. Studies of Medicare claims data indicate that application of peripheral intervention procedures varies >14-fold between various parts of the country.¹ Some of those from interventional subspecialties (primarily interventional radiology and cardiology) emphasize the major benefits now available from endovascular procedures, including the use of stents. They argue that revascularization offers the potential to improve or reverse renovascular hypertension, to salvage or preserve the renal circulation and renal function, and to improve the management of patients with refractory forms of congestive heart failure.² A recent review of the use of percutaneous renal artery procedures among Medicare beneficiaries confirms a rise from 7660 claims in 1996 to 18 520 claims in 2000, primarily because of a 2.8-fold increase in procedures by interventional cardiologists.³ Many in the nephrology community review the same published literature and reach nearly opposite conclusions. They argue that recent prospective studies fail to reveal major benefits of blood pressure control related to renal revascularization, that the risks of complications from interventional procedures are substantial, including uncommon but sometimes devastating loss of renal function resulting from atheroembolic disease.⁴ Despite a wave of enthusiasm in the early 1990s to identify and reverse "ischemic nephropathy" for patients with advanced kidney disease, disappointing results after intervention have made many nephrologists more conservative toward renal intervention than before.⁵

Where are we now with regard to our understanding of renal artery disease? This discussion addresses advances related to renovascular hypertension, ischemic nephropathy,

and cardiovascular disease risk associated with renovascular disease. Detailed examination of evolving imaging methods is beyond the scope of this review. More than ever, clinicians caring for patients with renal arterial disease need to balance carefully the risks and benefits of both medical management and the timing of renal revascularization. This review summarizes the current state of renovascular disease from this perspective, focusing primarily on the problem of atherosclerotic renal artery stenosis.

Epidemiology of Renovascular Disease

The vast majority of renal arterial lesions reflect either a variant of fibromuscular dysplasia (FMD) or atherosclerosis. Most FMD lesions are caused by medial fibroplasia (Figure 1A), consisting of banded lesions in the mid portion of the renal arteries. Screening angiography in potential kidney donors indicates that such lesions can be asymptomatic and may be detected in up to 3% to 6% of normotensive individuals.^{6,7} The characteristics of these lesions, the likelihood of progression, and their response to revascularization have been reviewed recently.⁸ When they reach sufficient hemodynamic severity to produce renovascular hypertension, they most commonly affect women between 15 and 50 years of age.⁹ When a population of "resistant hypertensives" were screened by angiography, 16% had FMD.¹⁰

Atherosclerotic disease is the predominant lesion detected in patients >50 years of age (Figure 1B). The prevalence and impact of these lesions appear to be increasing, in part because of the aging US population and improved survival from other vascular disease, including stroke and myocardial infarction. Population-based studies indicate that hemodynamically significant stenosis (>60% lumen occlusion based on Doppler flow studies) is common (6.8% of individuals >65 years of age, more common in men [9.1%] than women [5.5%]).¹¹ Renal artery stenosis resulting from atherosclerotic disease is common in individuals undergoing coronary angiography (18% to 20%)¹² and in those undergoing peripheral vascular angiography for occlusive disease of the aorta and legs (35% to 50%).¹³ The large majority of patients with atherosclerotic disease have preexisting hypertension, which is an independent predictor of the presence of renal arterial disease in most series.¹⁴

How often are elevated blood pressures in these studies caused by, or even remotely related to, the presence of the renal artery lesions? This question continues to plague clinical

From the Division of Nephrology and Hypertension, Mayo Clinic, Rochester, Minn.

Correspondence to Stephen C. Textor, MD, W9A, Mayo Clinic, Rochester, MN 55905. E-mail textor.stephen@mayo.edu
(*Circulation*. 2005;112:1362-1374.)

© 2005 American Heart Association, Inc.

Circulation is available at <http://www.circulationaha.org>

DOI: 10.1161/CIRCULATIONAHA.104.492348

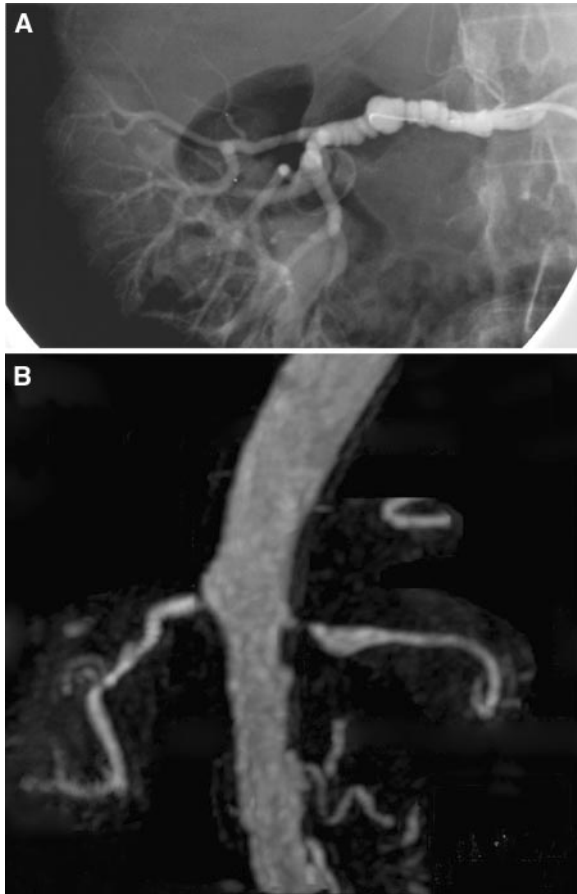


Figure 1. A, Angiogram from a patient with FMD with lesions characteristic of medial fibroplasia. The “string-of-beads” appearance typically develops in the mid portion of the vessel from circumferential webs within the vessel. These lesions may progress, particularly in smokers. B, MRA from an individual with atherosclerotic disease affecting the renal arteries. These lesions commonly arise near the ostium of the vessel and may be an extension of aortic plaques. Such lesions are detected as incidental findings in 6.8% of a general population >65 years of age and are even more prevalent in subjects with clinical coronary or peripheral vascular disease (see text).

cians and complicates decision making. Many authors emphasize the fact that identifying the presence of a renal artery lesion is quite separate from identifying true “renovascular hypertension,” which depends on the sequence of events resulting from reduction of perfusion pressure to the poststenotic kidney (see below).¹⁵ Series of hypertensive patients subjected to detailed evaluation suggest that <1% to 3% have renovascular hypertension.^{16,17} We have argued that atherosclerotic renal artery stenosis produces a spectrum of clinical syndromes ranging from incidental lesions to advanced disease as illustrated in Figure 2. Many individuals with atherosclerotic renal artery lesions have years of preexisting essential hypertension, active smoking histories, and coexisting diabetes mellitus.¹⁴ The age of interventional series has risen progressively over the past decade.¹⁸ The clinical picture of atherosclerotic renal arterial disease now is typified by an older person with years of preexisting hypertension detected only after abrupt acceleration of hypertension, sometimes with a new target event such as stroke. Many of those

Manifestations of Renovascular Disease

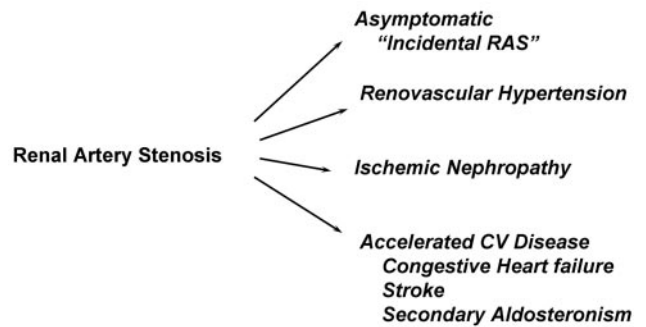


Figure 2. Schematic summary of the clinical manifestations of renovascular disease. For many individuals, these lesions are incidental findings of no hemodynamic importance. With increasing severity and duration, syndromes of renovascular hypertension and acceleration of cardiovascular morbidity can develop; in some cases, the viability of kidney function beyond the stenosis can be threatened (ischemic nephropathy). Clinicians routinely must make judgments about the role of vascular disease for a particular patient to establish the potential balance of risks and benefits from renal revascularization. Adapted from reference 118, with permission from Elsevier.

identified in the seventh and eighth decades likely have the opportunity to progress to clinical disease because of reduced mortality related to coronary and cerebrovascular diseases observed over the past 30 years. These features become central to estimating the likelihood of benefit with regard to renal revascularization and the practicalities of managing older subjects for whom “competing risks” sometimes may be so great as to outweigh the benefits of moderately improving blood pressure control.

Screening Studies and “Drive-By Angiography”

Identification of new hypertension in the 1970s commonly led to an extensive workup as a first step to “exclude” secondary causes of hypertension. The low diagnostic yield and high costs led to abandoning routine evaluation of such patients. Recent guidelines from the Joint National Commission (JNC VII) recommend only basic laboratory studies to define the level of kidney function, electrolyte status, glucose intolerance, lipid panel, and target organ damage.¹⁹ Recognition of the frequent coexistence of atherosclerosis in coronary and peripheral vascular beds has led some to recommend including routine aortography as part of angiographic studies.²⁰ The additional contrast burden and risks induced by including an aortogram are low. The quality of images appears satisfactory in most cases in several series. It may be argued that identification of unsuspected lesions provides important prognostic information and can determine the need for follow-up with regard to disease progression. Whether incidentally detected renal arterial lesions should be treated with endovascular stent procedures is highly controversial.^{4,21} Our view is that, although an aortogram is relatively benign in itself, endovascular intervention carries definite risks that should be weighed against the likely benefits, exactly as one would do for any other vascular lesion (see below).

Pathophysiology of Renovascular Hypertension

The seminal studies of Goldblatt et al²² in the 1930s demonstrate that reduction of perfusion to the kidney can produce sustained elevation of arterial pressure. Later work identified activation of the renin-angiotensin-aldosterone system as a central component of this process.^{23,24} Soon after the first orally active ACE inhibitor, captopril, was introduced, experimental studies confirmed that 2-kidney–1-clip renovascular hypertension in the rat could be prevented indefinitely by blocking this system.²³ Recent studies in “knockout” mice without angiotensin type 1 receptors confirm that renal artery clipping requires these receptors to produce 2-kidney–1-clip hypertension.²⁵

A series of studies indicates further that 2-kidney–1-clip hypertension (analogous to unilateral renovascular hypertension in humans) differs from 1-kidney–1-clip models.²⁶ In unilateral renal artery stenosis and its experimental correlate, 2-kidney–1-clip hypertension, the rise in blood pressure is associated with elevated plasma renin activity. The nonstenotic kidney is subjected to higher perfusion pressures and responds with “pressure natriuresis” that lowers the blood pressure by excreting sodium. The fall in pressure, however, again reduces perfusion to the stenotic kidney. Decreased renal perfusion pressure, in turn, drives the release of renin. The ability of the nonstenotic kidney to respond to elevated blood pressure with pressure natriuresis is impaired, partly as a result of elevated angiotensin II levels.²⁷ The latter not only directly stimulates aldosterone secretion and distal sodium reabsorption but also causes renal vasoconstriction that reduces plasma flow and enhances sodium reabsorption in both proximal and distal tubules. Thus, this model of renovascular hypertension is angiotensin II dependent and characterized by elevated plasma renin activity.²⁸

In contrast, experimental 1-kidney–1-clip hypertension reflects a balance between angiotensin II–dependent and volume-dependent mechanisms.²⁶ This process in humans corresponds to bilateral renal arterial disease or stenosis to a solitary functioning kidney. In the absence of a normally perfused contralateral kidney, 1-kidney–1-clip hypertension cannot excrete sodium in response to the rise in arterial pressure from angiotensin II. Sodium and water retention lead to volume expansion as the primary mechanism for hypertension. This expansion suppresses plasma renin activity and lowers angiotensin II levels. Hence, plasma renin activity is normal, and blood pressure does not fall with angiotensin receptor blockade.²⁹ Depletion of sodium with reduced intake and/or diuretic administration converts this sodium-dependent model of renovascular hypertension to an angiotensin-dependent model.²⁶ Hence, sodium and/or volume expansion is capable of suppressing the renin-angiotensin system, even in renovascular disease. Mechanistic differences underlying unilateral and bilateral disease and, specifically, renin release have consequences for diagnostic testing that relies on renin measurements, as discussed below.

Human studies tend to support these observations. Studies of renal vein renin activity indicate that a stimulatory maneuver such as diuretic and/or a vasodilator administration raises renin activity in the affected kidney, which is suppressed before the maneuver.³⁰ A large body of experience indicates

that when renal vein renin levels lateralize to one kidney, the likelihood of a favorable blood pressure response to renal revascularization exceeds 90%. Remarkably, when these levels fail to lateralize, the likelihood of benefit still approaches 50%, partly because of failure to standardize renin sampling sufficiently and to achieve sodium depletion. As a result, the ambiguity of these studies and the fact that sodium retention develops even more commonly in patients with renal dysfunction make measurement of renal vein renin levels of limited value in practice. Confirming lateralization of renin production, however, does have a role in planning more drastic interventions such as unilateral nephrectomy for a “pressor kidney.”^{31,32}

Recruitment of Additional Pressor Mechanisms

Activation of the renin-angiotensin system in response to renal artery stenosis is an essential but transient phenomenon. In some models, renin activity returns to “normal” levels for a period of time during which removal of the renal artery lesion still allows recovery to normal blood pressures.³³ Recent studies in experimental models demonstrate “recruitment” of additional vasoconstrictive mechanisms, including oxidative stress, that no longer depend directly on angiotensin II.³⁴ Angiotensin II is known to alter vascular oxidative-reduction pathways by changing the kinetics of NAD(P)H, leading to overproduction of reactive oxygen species such as peroxynitrite, hydroxyl radical, and hydrogen peroxide.³⁵ In the pig model, the rise in arterial pressure correlates most closely with the rise in stable metabolites of these oxidative products such as isoprostanes.³⁶ Similar processes underlie the “slow response” to angiotensin II, leading some authors to believe that even suppressor levels of angiotensin are fundamentally responsible for vascular resistance in this phase.³⁷ Some of these systems are shown in Figure 3. Recent work indicates that endothelial dysfunction, reflecting impaired vasodilatation to acetylcholine, is found in human patients with renovascular hypertension. This endothelial disturbance can improve after successful renal revascularization.^{38,39} Experimental studies in a pig model of renovascular disease emphasize that cholesterol feeding itself can produce endothelial abnormalities that are magnified in the presence of renal artery stenosis.³⁶ These data support the hypothesis that complex interactions between vascular injury related to dyslipidemia, smoking, diabetes, and blood pressure itself accelerate target organ injury related to renovascular hypertension.

Other systems, including the release of endothelium-derived endothelin, appear to be activated during the development of renovascular hypertension, particularly in the presence of atherosclerosis.⁴⁰ Increased activity of the sympathetic nervous system is commonly observed, potentially mediated by disturbed afferent signals from the underperfused kidney and/or augmentation of nerve stimuli in the presence of angiotensin II.⁴¹ Aldosterone levels appear to be higher in patients with renovascular hypertension during the long term.⁴² This hormone is now recognized to participate in regulation of tissue fibrosis and left ventricular hypertrophy, in addition to its effects on sodium retention.⁴³

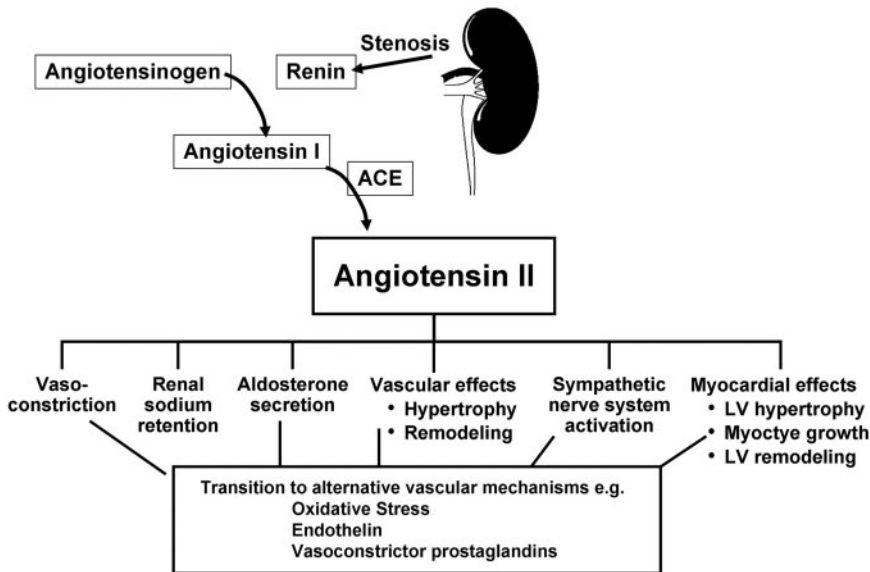


Figure 3. Schematic of pressor mechanisms identified in renovascular hypertension. Reduced perfusion to the kidney activates release of renin, which ultimately amplifies systemic signals to restore renal artery pressures. These signals include sodium retention and recruitment of additional vasoconstrictor pathways (see text). Blockade of angiotensin generation or genetic knockout of angiotensin receptors can prevent this sequence, although some of the later signals no longer depend entirely on the renin-angiotensin system.

Impaired Renal Function

For the purposes of this discussion, “ischemic nephropathy” refers to impairment of renal function beyond occlusive disease of the main renal arteries. It should be emphasized that deterioration of renal function does not necessarily reflect true “ischemia.” Because a major function of the kidney is filtration, blood flow to the kidney provides a vast oversupply of oxygenated blood per se. Less than 10% of the blood flow is needed for metabolic requirements of the kidney.⁴⁴ Some authors prefer the term “azotemic renovascular disease” to avoid the supposition that loss of renal viability is necessarily related directly to impaired oxygenation.⁴⁵ To materially affect renal function on a vascular basis alone, the entire renal mass must be affected. Thus, a reduction in glomerular filtration rate (GFR) for patients with unilateral renovascular disease implies some other parenchymal disease in the contralateral kidney and rarely improves after renal revascularization.⁴⁶ Reduction of systemic arterial pressures proximal to critical lesions thereby induces hypoperfusion to the distal arterial segments, sometimes below levels needed for autoregulation of blood flow. Reduction of perfusion pressure to the kidney invariably activates pressor mechanisms to restore renal perfusion, including activation of the renin-angiotensin system, adrenergic stimuli, and other mechanisms.³⁴

Further occlusion again reduces perfusion to the renal circulation and triggers a repeated cycle of elevation of systemic pressures. Unless interrupted, this sequence ultimately produces malignant-phase hypertension.

In clinical settings, antihypertensive therapy is directed at lowering systemic pressures to achieve proven benefits in reducing cardiovascular morbidity. The price of lowering pressure for patients with renovascular disease may be underperfusion of the poststenotic kidney(s). This can develop during therapy with any antihypertensive agent and can produce a loss of GFR when perfusion pressures fall below those needed for autoregulation.⁴⁷ Revascularization of the kidney can remove the pressure dependence of GFR in such patients.^{48,49}

What are the pathways by which renal interstitial fibrosis develops beyond a vascular lesion? Recent studies in a swine model of atherosclerosis shed some light on this process.³⁴ When cholesterol feeding is combined with renal artery stenosis, magnification of oxidative stress pathways develops. Tissue fibrogenic cytokines are stimulated in the kidney, reflected by increased transforming growth factor- β , nuclear factor- κ B pathways, and others.³⁶ Pathways normally leading to clearance of apoptotic stimuli such as metalloproteinases sometimes are suppressed within the kidney.⁵⁰ Experimental studies demonstrate that repetitive acute insults to the rat kidney can produce acute tubular injury capable of recovery after each episode. However, these repeated insults are capable of provoking mechanisms that produce tubulointerstitial fibrosis much later, which is no longer reversible.⁵¹ Hence, episodic tissue underperfusion, especially when combined with early atherogenic stimuli, activates an entire fibrogenic cascade in the kidney.

The complexity and variability of this process between individuals cannot be overemphasized. Although occasionally patients with advanced renal dysfunction and high-grade vascular occlusion respond with meaningful recovery of kidney function after renal revascularization, this result is not common. In most series of patients with impaired renal function before revascularization, little or no recovery of GFR follows either surgical or endovascular restoration of blood flow.⁴⁵ Establishing the time course and governing factors related to postocclusive renal fibrosis, determining the potential salvageability of kidney tissue, and recovery of glomerular filtration represent important areas of ongoing research in this field.⁵²

Clinical Manifestations of Renovascular Disease

Early studies of hypertensive patients found few major differences between clinical manifestations of patients referred for renovascular surgery and those with essential hypertension.⁵³ A predilection for hypokalemia, an absent family history of hypertension, and several other features favor renovascular hypertension, but these differences are

small and have low predictive value. Recent studies in patients referred for "resistant hypertension" indicate that a clinical score comprising the presence of clinical vascular disease, abdominal bruits, body weight, smoking, and several other elements is nearly as predictive of renovascular disease (>50%) as findings on nuclear renography.¹⁰

More recent data indicate that renovascular disease is associated with increased sympathetic neural activity, reflected as blood pressure variability and larger standard deviations during 24-hour ambulatory blood pressure monitoring.⁴² Target organ injury, including left ventricular hypertrophy, is more severe than that observed with essential hypertension, despite similar levels of "casual blood pressure." Patients describe "flushing," rapid blood pressure swings, and autonomic instability sometimes suggestive of pheochromocytoma. The usual nocturnal blood pressure fall often is absent, producing more sustained hypertension during the 24-hour period. When blood pressure rises rapidly in the presence of high angiotensin II levels, a syndrome of hyponatremia and malignant-phase hypertension has been reported.⁵⁴

Atherosclerotic renovascular disease is commonly associated with reduced GFR, albeit to modest degrees. Studies of renal blood flow and the response to vasodilators (eg, papaverine) using intravascular ultrasound demonstrate reduced flow "reserve" beyond high-grade vascular stenosis.⁵⁵ Successful revascularization restores the response to vasodilation. Careful studies of transplanted kidneys with measurement of both blood flow and GFR before and after angioplasty indicate that percutaneous transluminal renal angioplasty (PTRA) is capable of restoring laminar blood flow and sodium excretion, even without measurable change in GFR.⁵⁶ Hence, blood flow and GFR can be dissociated under conditions of reduced perfusion pressure. This is regularly observed during administration of agents blocking the renin-angiotensin system. Removal of angiotensin II, which acts preferentially on the efferent vasculature beyond the glomerulus, can produce sudden drops in filtration pressure and therefore a fall in GFR without much change in systemic pressure. This commonly leads to a rise in serum creatinine within the first few days of either ACE inhibitor or angiotensin receptor blockade therapy.⁵⁷⁻⁶⁰ In a group of 258 subjects subjected to endovascular stenting between 1996 and 2000, the mean serum creatinine was 1.6 mg/dL (Figure 4). When the Modified Diet in Renal Disease equation is applied to calculate GFR, the vast majority (84.8%) of these individuals had stage 3 to 5 chronic kidney disease, with GFR levels <60 mL · min⁻¹ · 1.73 m⁻². Recent epidemiological data reinforce the observation that reduced GFR in these ranges is a strong independent predictor of cardiovascular risk. Hence, it is not surprising that even for successfully treated individuals with renal artery stenosis, subsequent cardiovascular morbidity and mortality rises in close parallel with final levels of kidney function.⁶¹ These observations offer an important corollary to the recognition that patients with atherosclerotic renovascular disease do not commonly progress to end-stage renal disease. Instead, they are far more likely to be at accelerated risk for stroke, congestive heart failure, and myocardial infarction.

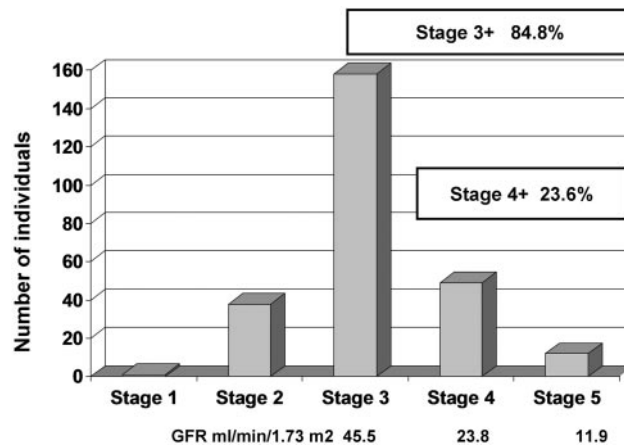


Figure 4. Stages of chronic kidney disease as estimated by the Modification of Diet in Renal Disease equation in 258 individuals undergoing renal artery stenting. Median age was 74 years; mean serum creatinine was 1.6 mg/dL. These data underscore the importance of recognizing impaired kidney function as a risk factor for cardiovascular events and the level of renal dysfunction present in older subjects with renovascular disease.

Some patients develop refractory fluid retention related to impaired renal perfusion. This sometimes presents as "treatment-resistant" circulatory congestion, often out of proportion to the degree of myocardial pump failure. This may simply reflect sodium avidity resulting from reduced renal perfusion pressure or, in some cases, acute decompensation of left ventricular function related to abrupt rises in arterial pressure during volume expansion.⁶² Empirically, this diagnosis is confirmed by clinical improvement after successful renal revascularization, which can break the pattern of repeated hospital admissions for congestive heart failure.^{2,63} As a practical matter, the course of evaluating patients with unexplained renal dysfunction, rapidly changing arterial pressures, and/or treatment-resistant circulatory congestion should include measures to exclude clinically important renovascular disease. Some series report a prevalence of renal artery stenosis exceeding 30% of patients admitted to hospital for congestive heart failure.⁶⁴

Diagnostic Tests and Imaging

Numerous studies in the 1970s and 1980s focused on functional measurement of activation of the renin-angiotensin system as a diagnostic clue to renovascular hypertension. These included stimulation (with diuretics, administration of ACE inhibitors) and blockade with angiotensin receptor blockers (eg, substituted peptides such as Sar-1-ala-8-angiotensin II) sometimes combined with functional or radionuclide imaging.⁶⁵⁻⁶⁷ Although these provide insight into the dynamics of blood pressure control and effects on the kidney, they generally fail as diagnostic studies because of the broad overlap with other causes of hypertension and the confusion presented by the changing conditions of study, as noted above. Their predictive value related to the outcome of renovascular intervention has typically been <50%.⁶⁸ As noted below, critical decisions about vascular intervention now more often revolve around the timing than the specific diagnosis of renovascular hypertension.

The past decade has brought major advances in noninvasive imaging of the renal vasculature. Although a detailed discussion of these techniques is beyond the scope of this review, several points merit emphasis with regard to distinguishing renal artery stenosis and true renovascular hypertension. Remarkably, many renal artery lesions are discovered incidentally during vascular imaging for other purposes.

It may be argued that the major responsibility of the clinician is to decide responsibly when to follow through with additional studies and/or to proceed to further vascular intervention procedures. The threshold for performing imaging procedures depends primarily on the importance of excluding high-grade stenosis before proceeding on long-term medical therapy and on one's commitment to acting on the information obtained, ie, to proceed with revascularization procedures. (Our own indications for considering revascularization, and therefore for imaging the renal vessels, are summarized in Table 3.) The specific imaging modality depends heavily on precisely what clinical issue is foremost, as we have discussed.⁶⁹ When the primary question is whether renovascular disease is bilateral or unilateral, a direct imaging mode such as MR angiography (MRA) likely provides far more useful information than a captopril renogram.

MRA and CT angiography provide detailed images of the aorta and renal arteries, often allowing identification of multiple vessels. Gadolinium has little nephrotoxicity, and MRA allows the most detailed vascular imaging in patients with renal insufficiency without the hazard of contrast nephrotoxicity. Both CT and MR allow gross estimates of renal size, overall anatomy, and filtration. Several published series indicate that both MRA and CTA provide reliable identification of atherosclerotic renal artery disease of the proximal arterial segments with sensitivity and specificity >90%.^{70,71} A recent prospective study of >356 patients subjected to both examinations and digital angiography suggested substantially lower (64%) sensitivity.⁷² This observation must be tempered by the fact that ≈38% of renovascular lesions identified were due to FMD in medial and distal segments, areas known to be less well visualized by MRA.

Doppler ultrasound provides high specificity in highly competent laboratories. When vessels can be correctly identified and studied, a positive finding is rarely disproved by angiography. Although ultrasound provides only minimal information about the function of kidneys, it can provide reliable hemodynamic assessment of arterial lesions and identify gross structural abnormalities related to kidney size. Some authors argue that Doppler examinations provide more physiological and relevant information than even intra-arterial angiography and thereby should be considered the true gold standard.⁷³ Measurement of diastolic blood flow velocity (usually expressed as resistive index) can indicate small-vessel disease and parenchymal fibrosis. When this exceeds 0.80, the likelihood of improved blood pressure or improved renal function after renal revascularization is low.⁷⁴ Limitations of Doppler ultrasound are often related to inadequate examinations, particularly in obese individuals. It is among the least expensive means of evaluating the vasculature and can be applied to serial measurements of stenotic vessels to monitor disease progression.

TABLE 1. Management of Renovascular Hypertension

Medical management
Antihypertensive drug therapy
ACE inhibitors
Angiotensin receptor blockers
Calcium channel blockers
β-Blockers
Central sympathetic agents
α-Blocking agents
Diuretics
Vasodilators
Lipid-reducing agents
Statins
All others
Cardiovascular risk factor reduction
Withholding smoking
Renal revascularization
Endovascular procedures
PTRA
PTRA with stenting
Surgical procedures
Renal artery reconstruction (require aortic approach)
Renal endarterectomy
Transaortic endarterectomy
Resection and reanastomosis, suitable for focal lesions
Aortorenal bypass graft
Extra-anatomic procedures (may avoid direct manipulation of the aorta)
Splenorenal bypass graft
Hepatorenal bypass graft
Gastroduodenal, superior mesenteric, iliac-to-renal bypass grafts
Renal ablative surgery, removal of a "pressor" kidney
Nephrectomy, direct or laparoscopic
Partial nephrectomy

Adapted from reference 118, with permission from Elsevier.

Captopril renography is widely applied but has limited value, particularly in patients with renal insufficiency. If lesions are bilateral, no differences between kidneys may be identified.

Management of Renovascular Hypertension

Listed in Table 1 are several forms of therapy applied to renovascular hypertension. They are listed to underscore the broad range of tools available. It should be emphasized that therapy must be highly individualized, depending on the circumstances of the patient. Most patients will be treated with intensive medical intervention both before and after renal revascularization. Hence, clinicians face the responsibility mainly of establishing timing and risk-to-benefit ratios of both follow-up medical therapy and vascular intervention.

Medical Therapy of Renovascular Hypertension

Most patients with renal artery stenosis come from the population with preexisting essential hypertension and other

atherosclerotic disease. Hence, antihypertensive drug therapy, withholding tobacco use, and reducing LDL cholesterol are mainstays of treatment both before and after renal revascularization. Many older patients with renal arterial disease have reduced GFR, as illustrated in Figure 4. Selection of specific antihypertensive drug therapy is based not on the presence of renal artery stenosis but on comorbid disease risk. Current JNC VII guidelines propose target blood pressure levels of <130/80 mm Hg for individuals with measurable loss of kidney function.¹⁹ Some reports indicate that aggressive lipid reduction may lead to regression of atherosclerotic disease, which in fact has been observed sometimes in the renal arteries.⁷⁵

It is now evident that the renin-angiotensin-aldosterone system plays a major role in regulating vascular tone and sodium and water balance in many conditions. These include not only the clinical syndromes of renovascular hypertension but also proteinuric kidney disease (both diabetic and nondiabetic), left ventricular hypertrophy, and congestive heart failure. Specifically, elevated levels of angiotensin II and aldosterone lead to effects both through hypertensive injury and activation of profibrotic and atherosclerotic pathways.^{76,77} The latter includes stimulation of growth factors such as transforming growth factor- β , leading to inflammation, fibroblast formation, and collagen deposition. In the kidney, glomerulosclerosis and tubulointerstitial fibrosis ensue. In the heart, angiotensin II activation has been associated with myocyte and left ventricular hypertrophy, collagen deposition, myocardial fibrosis,^{78,79} and atherosclerotic and prothrombotic effects in the coronary circulation.

Consequently, many patients with renovascular disease will be candidates for ACE inhibitor therapy (and/or angiotensin receptor blockade) on the basis of other compelling indications such as diabetes, congestive heart failure, or high cardiovascular risk. Clinical data suggest that survival of patients with renovascular hypertension is better when ACE inhibitors are part of therapy than when they are not.⁸⁰ The clinical outcomes and survival during medical therapy of high-grade renal artery stenosis appear to be comparable to those with revascularization when goal blood pressures are achieved.^{81–83} Importantly, most patients will continue to require complex antihypertensive regimens after successful renal revascularization.^{84,85} Although some reports indicate that fewer drugs may be required, this is not universally observed. The major additional benefit of renal revascularization in many cases is the ability to achieve goal blood pressures. Whether those individuals already treated effectively to goal blood pressures gain much from revascularization is debatable.

Role of ACE Inhibition and Angiotensin Receptor Blockade

The introduction of antihypertensive agents capable of blocking the renin-angiotensin system has been especially important for patients with renovascular hypertension. Starting in the early 1980s, several trials evaluating the use of ACE inhibitors to treat renovascular hypertension reported marked improvement in blood pressure control compared with previous regimens that often failed.^{86,87} As a result of wider use of

these agents for other indications, it is likely that many individuals with renovascular hypertension are never detected. They are simply treated.

A major concern in the use of ACE inhibitors for renovascular hypertension is their potential to cause functional acute renal failure.⁸⁸ The mechanism of acute renal failure relates to the inhibition of the compensatory mechanisms that develop beyond a stenotic lesion. Poststenotic reduction in renal perfusion pressures stimulates release of renin and angiotensin II, resulting in vasoconstriction of the efferent arteriole that preserves glomerular capillary filtration pressure. Administration of ACE inhibitors (or angiotensin II receptor blockers) and the subsequent relaxation of the efferent arteriole can reduce glomerular capillary hydrostatic pressure enough to cause a decrease in glomerular ultrafiltration. This loss of filtration produces a rise in serum creatinine. The distinctive feature of ACE inhibitors is their ability to lower transcapillary filtration pressures by their effects on efferent arteriolar tone and to decrease GFR without major changes in blood flow to the glomerulus.⁸⁹ Filtration usually recovers rapidly after discontinuation of the offending drug.⁵⁷

A fall in GFR during antihypertensive therapy is not specific to ACE inhibitors. Whenever drug therapy reduces systemic blood pressure sufficiently to impair blood flow beyond a stenotic lesion beyond the range of autoregulation, renal function declines.⁹⁰ Remarkably, literature reports of irreversible renal insufficiency resulting from renal artery thrombosis are rare.⁹¹ Under these conditions, both GFR and blood flow seem to be severely compromised, resulting in irreversible renal damage.

As a result, it is essential that clinicians exert caution when starting an ACE inhibitor in patients with known or suspected renal artery disease with close follow-up of kidney function and potassium levels.⁵⁹ Observing a significant fall in GFR (commonly defined as a 30% fall in calculated GFR or a rise in serum creatinine >0.5 mg/dL) itself may be an indication to consider the need for renal revascularization.

In unilateral renal artery stenosis, the affected kidney frequently has reduced filtration without measurable changes in creatinine.⁹² Changes in total GFR are minor, presumably because of a compensatory increase in GFR by the contralateral kidney. Clinically significant loss of GFR during treatment with ACE inhibitors happens in only a fraction of treated patients, usually in those with vascular stenosis that affects the entire functional renal mass (bilateral renal artery stenosis or stenosis to a solitary kidney). Initial studies reported renal failure in one fourth to one third of patients with either bilateral renal artery stenosis or stenosis to a solitary kidney who received ACE.⁶⁰ In a review, 269 patients treated with the captopril Hollenberg reported a lower incidence: Of 136 (51%) patients with either bilateral renal artery stenosis or stenosis to a solitary kidney, only 8 (5.8%) developed progressive acute renal failure within the first month of treatment.⁹³ In all but 1 patient, the changes in creatinine were reversible after discontinuation of captopril. The efficacy and safety of ACE inhibitors were examined in a prospective randomized double-blind study of 75 patients with renovascular hypertension that compared an enalapril-based regimen with triple therapy without an ACE inhibitor.⁸⁷

An increase in the serum creatinine level was observed in 10 patients (20%) in the enalapril group compared with 3% in the control group. No oliguric renal failure occurred in the enalapril-treated group, although the largest increase in creatinine was noted in this group, specifically among the patients with bilateral renal artery stenosis and preexisting renal insufficiency. Taken together, ACE inhibitors usually can be used for treatment of renovascular hypertension without important loss of GFR.

In addition to global renal ischemia (either bilateral renal artery stenosis or stenosis to a solitary kidney), recognized risk factors that predispose to developing renal failure during ACE inhibition include congestive heart failure, treatment with vasodilators or diuretics, and volume contraction. Patients with CHF sometimes develop an exaggerated response to blood pressure medications and a propensity to develop hypotensive episode that may precipitate acute deterioration of renal function. In addition, standard treatment of these patients with sodium restriction and diuretics can lead to chronic volume depletion and inability to tolerate further volume loss that may occur with intercurrent illness such as vomiting and diarrhea. Remarkably, prospective trials of ACE inhibition in patients with congestive heart failure are reassuring with respect to the percentage of patients who developed a rise in creatinine leading to withdrawal of these agents (1% to 2%).⁹⁴

In current practice, the emphasis is on early recognition of potential risk factors for ACE inhibitor–induced renal side effects and close monitoring of this group of patients.⁹⁴ In high-risk patients, particularly those with heart failure, most investigators would agree that diuretics should be withheld before initiation of ACE inhibition.⁹⁵ Some patients with elevated creatinine can be treated with discontinuation of diuretics rather than ACE inhibitors.⁹⁶ Intercurrent illnesses leading to volume depletion (vomiting, diarrhea) and consequent rise in creatinine should be treated with saline infusion and discontinuation of ACE inhibitors during the acute illness. With a reduction in perfusion pressure, renal blood flow becomes highly dependent on vasodilatory prostaglandins.⁹⁷ Concurrent use of nonsteroidal antiinflammatory drugs should be strongly discouraged because acute reduction in renal function may ensue. Volume management with judicious use of diuretics and close monitoring of renal function is crucial during the chronic treatment with ACE inhibitors in these patients.

Role of Renal Revascularization

At first glance, restoring the renal circulation in the presence of occlusive vascular disease ought to provide obvious therapeutic benefit. Many patients with intractable renovascular hypertension and some with renal insufficiency experience major recovery. In practice, however, both endovascular and surgical procedures continue to introduce costs and risks that limit their universal application. This is particularly the case for many renovascular lesions that pose no immediate hazard or risk of progression. Therefore, establishing appropriate timing and the optimal role for renal revascularization has proved to be daunting. At the base of this debate lies the ambiguity of both the benefits obtained and the risks posed by

manipulation of the diseased aorta and renal arteries. Sufficient prospective, controlled data are not yet available to provide clear guidelines. A recently approved prospective trial, Cardiovascular Outcomes in Renal Artery Lesions (CORAL), beginning in 2005 will examine the effect of intensive medical management with or without stenting on cardiovascular events. The simple fact that such a randomized trial can be approved underscores the ambiguity remaining in this field. Hence, we will attempt to summarize current data into a perspective useful to the active clinician.

Surgery, PTRAs, and Stenting

Beginning in the 1980s, percutaneous procedures offered the potential to open partially occluded vessels in patients for whom surgical risks prevented open repair. Renal artery surgery still offers major benefits for patients undergoing surgical repair of the aorta, for patients undergoing nephrectomy, and for patients with complex disease of the renal arteries, eg, associated renal artery aneurysm or failed endovascular procedures.^{32,98,99} Surgical procedures may include renal artery bypass grafting, endarterectomy, or occasionally “extra-anatomic” repair using anastomosis to the hepatic or splenic arteries. The introduction of stents has now extended the efficacy of endovascular techniques to ostial lesions with technical success possible in nearly 100%. A randomized study of 85 patients with ostial atherosclerotic renal artery stenosis reported improved primary patency in patients treated with stents (75%) compared with angioplasty alone (29%) at a 6-month follow-up.¹⁰⁰ Remarkably, improved vessel patency in patients who were treated with stents did not result in better blood pressure and renal outcomes, although longer follow-up was not available. With continued improvement in technique, expanded use of endovascular procedures has led to a major decline in surgical procedures for reconstruction of the renal arteries over the past decade.³

Results of PTRAs with and without stenting have been summarized in several publications.^{18,101} In most instances, authors consider hypertension outcomes in terms of cured (normal arterial pressures without antihypertensive therapy), improved (usually defined as lower arterial pressures by at least 10 mm Hg during follow-up visits with the same medications or similar pressures with reduced medication requirements), or no change. Unfortunately, details about methods of measuring blood pressure, length of follow-up, and specific medication dosage and class vary widely between studies, as has been reviewed.¹⁰² Several of the most recent series indicate that hypertension is cured only rarely (<10%) in patients with atherosclerotic renovascular disease. Ranges for improved vary from 29% to 75%. Little or no change in either blood pressure control or medication requirements is reported in 30% (range, 0% to 54%) of treated patients. Overall, group blood pressure changes commonly approach 25/10 mm Hg reduction.¹⁰³ Such improvements in blood pressure control for an individual can mean major benefits with regard to reduced risk of stroke, congestive cardiac failure, and reduced medication requirements (Figure 5).

Remarkably, only 3 randomized trials with a total of 210 patients have compared medical management versus PTRAs prospectively.^{104–106} To their credit, these trials attempted to

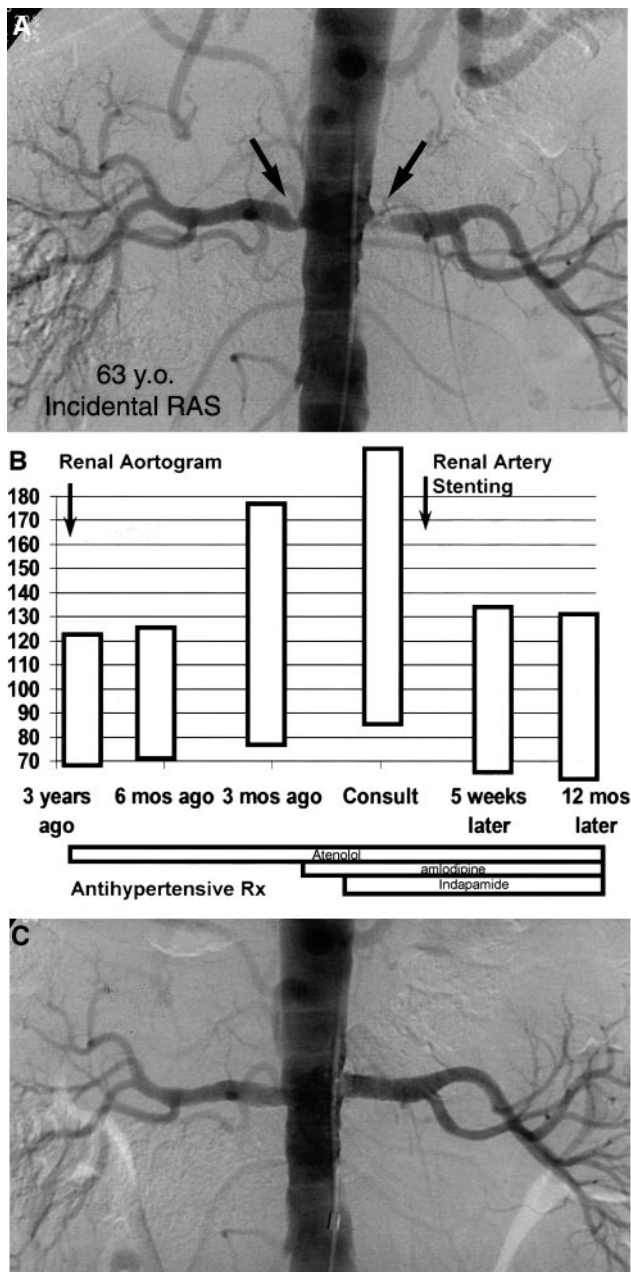


Figure 5. A, B, Angiograms and blood pressures in a 63-year-old man with incidentally identified renal artery stenosis during coronary angiography. Pressures were easily controlled for several years with minimal medication requirements. In this case, renovascular hypertension developed with rapidly rising arterial pressures refractory to 3 medications, which responded to effective endovascular stenting (C). Reprinted from Textor¹⁷ with permission.

standardize blood pressure measurement before and after revascularization. The results of these trials are summarized in Table 2. Compared with retrospective reports, the results of these prospective studies indicate lower benefits from angioplasty than expected. Taken individually, these studies demonstrate modest, if any, advantage of vascular intervention over medical treatment in blood pressure control. One trial demonstrated improved blood pressure control for patients with bilateral but not unilateral renovascular disease. The

validity of this conclusion must be interpreted within the limitations of each of these trials. They included a small number of patients, relatively short follow-up, and failure to report pre-enrollment changes in blood pressure and creatinine over time, which might have accounted for differences between the groups at the time of enrollment.¹⁰⁷ In 2 of these studies, 7 of 26 (27%) and 22 of 50 (44%) patients who were initially assigned to medical therapy crossed over to the PTR group because of refractory hypertension or progressive occlusive disease. Crossover patients were included in the medical group in each case for intention-to-treat analysis. From this point of view, results in crossover patients support the role of PTR for a subset of patients with renovascular hypertension refractory to medical therapy. Two meta-analyses of these trials independently reported that, compared with medical therapy, PTR was more effective in reducing blood pressure. In one study, comparison of the mean change (baseline to 6 months) between groups showed greater reductions in both systolic (6.3 mm Hg; $P=0.02$) and diastolic (3.3 mm Hg; $P=0.03$) pressures in the angioplasty group.¹⁰⁸ No clear benefit in terms of serum creatinine change from baseline was observed.

Outcomes with regard to renal function are more ambiguous. Revascularization of atherosclerotic renal arterial lesions for patients with impaired renal function consistently demonstrates, on average, no net change in renal function as determined by serum creatinine or calculated GFR.^{45,103,109} As we and others have observed, failure to detect group changes obscures the fact that some patients experience major improvements in kidney function. In a series of 304 patients with serum creatinine ≥ 2.0 mg/dL, 27% experienced a meaningful improvement in creatinine (from 4.4 to 2.3 mg/dL). The bulk of patients (52.6%) had little net change, defined as a change < 1.0 mg/dL, but may be considered to be at less risk of disease progression. The explanation for failure to see overall mean changes derives from the ubiquitous third outcome, namely a rapid further deterioration in kidney function in a subset of patients (20%) with a rise from 3.1 to 6.8 mg/dL.⁴⁵ Essentially identical results appear from series with PTR (22% reported as worse).¹¹⁰ The explanation for this effect is often attributed to atheroembolic disease but may reflect multiple mechanisms, including vessel dissection or contrast nephropathy. The potential for serious deterioration in kidney function, sometimes developing weeks after the procedure (Figure 6), underscores the need to select patients carefully for vascular procedures in the kidney.

For patients with congestive heart failure and repeated admissions for pulmonary edema associated with renal artery stenosis, successful stenting can produce improved volume management, restored sensitivity to diuretics, and lowered rehospitalization rates.^{111,112} In a series of 39 patients with refractory congestive heart failure, 20 (51.4%) had clinically important improvement in renal function after stenting.¹¹³ Identifying patients likely to have improved blood pressures and renal function after revascularization remains a challenge. An atrophic kidney (< 8 cm) is unlikely to improve after revascularization. Radermacher and colleagues⁷⁴ indicate that evaluation of the resistive index by Doppler ultrasound provides a measure of diastolic flows to the kidney and

TABLE 2. Prospective Randomized Trials Comparing Medical Treatment and PTRAs for Atherosclerotic Renal Artery Stenosis

Medical Therapy vs PTRAs					
Trial Duration, mo (reference)	Classification Before Randomization	Patients, n	BP Outcome, mm Hg	Serum Creatinine, mmol/L, or Creatinine Clearance, mL/min	Drug Regimen
12 (104)	Unilateral	14 vs 13	161/88 vs 173/95 (NS)	160 vs 146 mmol/L (NS)	Atenolol + diuretic + CCB ± methyldopa ± prazosin; ACEI not allowed
	Bilateral	16 vs 12	171/91 vs 152/83 (<0.005)	152 vs 192 mmol/L (NS)	
6 (106)	Unilateral	26 vs 23	141/84 vs 140/81 (NS)	74 vs 77 mL/min (NS)	Nifedipine ± clonidine ± prazosin ± atenolol ± furosemide ± enalapril
12 (105)	Unilateral and bilateral	50 vs 56	At 3 mo, 163/88 vs 169/89 (NS); at 12 mo, 162/88 vs 152/84 (NS)	At 3 mo, 59 vs 70 mL/min (0.03); at 12 mo, 62 vs 70 mL/min (NS)	Amlodipine + atenolol or enalapril + diuretic

BP indicates blood pressure; CCB, calcium channel blockers; and ACEI, ACE inhibitor. NS is $P \geq 0.05$.

reflects injury to the small vessels. A resistive index >0.80 suggests that intrinsic renal injury does not respond and argues for lower probability of either improved kidney function or blood pressure after endovascular stenting. Complications of endovascular stenting have been reviewed in several series. These include significant bleeding and vascular injury, segmental infarction, systemic atheroemboli, aortic dissection, stent migration, and thrombosis, to name a few.¹¹⁴ Studies using distal protection devices to capture dislodged atherosclerotic debris are only now beginning.

Restenosis continues to be identified in 10% to 15% of patients, despite excellent initial results of technical vessel patency. Whether this will abate with coated stent material remains to be verified in the renal arterial bed. These typically develop within the first 6 months and may be treated with repeated angioplasty. These observations underscore the need for serial follow-up of patients with renovascular disease regardless of the therapy chosen. Stenotic lesions are capable of progressing or developing restenosis over time. Hence, serial studies of both stented and nonstented lesions are an

important element of management, particularly when suboptimal responses to therapy are evaluated.

Long-Term Outcomes and Rational Management of Renovascular Disease

The goals of therapy for renovascular hypertension center on effective reduction of blood pressure and stabilization of renal function. Atherosclerotic renovascular disease reflects a high overall atherosclerotic burden manifest as coronary, cerebrovascular, and peripheral vascular disease. Hence, outcomes for patients in this age group are determined mainly by cardiovascular events, which appear closely related to the level of kidney function.^{61,115} It should be emphasized that patients with renovascular disease affecting the entire renal mass, with either bilateral disease or stenosis to a solitary functioning kidney, have a worse prognosis.¹¹⁶ These observations hold regardless of whether the kidney is revascularized.⁸¹ To date, no major differences in patient survival are evident between patients subjected to either surgical or endovascular procedures, although few randomized trials have addressed this issue directly. Resolution of this issue with current patient demographics and optimized medical therapy is a major objective of the CORAL study about to begin.

As with most complex disorders, management decisions must be highly individualized for patients with renovascular disease. It is essential to consider renal arterial disease as one aspect of atherosclerotic disease. Summarized in Table 3 are current indications for considering renal revascularization in our own practice. Regardless of how such patients are identified, close follow-up is essential to determine both the stability and recurrence of vascular lesions in the kidney. The case shown in Figure 5 illustrates the point that high-grade renal arterial disease discovered incidentally can pose no problem for either kidney function or blood pressure for several years. At one point, however, blood pressure began to accelerate and did not respond to the addition of several antihypertensive drugs.¹¹⁷ Such cases underscore the capacity for clinical circumstances to change and the need to manage vascular disease affecting the kidney carefully over time, as with any other vascular disorder. As long as blood pressure and kidney function are well maintained, expectant management appears to be entirely appropriate. It must be under-

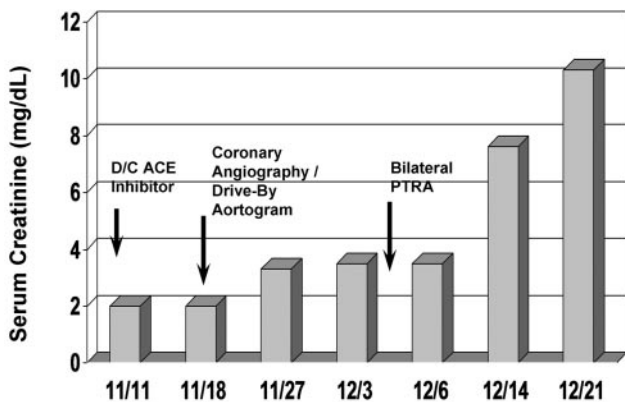


Figure 6. Serum creatinine values in a 63-year-old man with coronary disease and congestive cardiac failure subjected to bilateral PTRAs. Despite measures to avoid contrast nephropathy, serum creatinine rose after his diagnostic studies. Renal revascularization was followed by gradual but progressive loss of kidney function, reaching serum creatinine >10 mg/dL and requiring maintenance hemodialysis over the ensuing weeks. In most cases, these developments are attributed to atheroembolic renal disease. Such cases emphasize potential hazards of aortic manipulation in patients with extensive atherosclerosis.

TABLE 3. Indications for Renal Revascularization

Resistant hypertension
Failure of medical therapy despite full doses of ≥ 3 drugs, including diuretic
Compelling need for ACE inhibition/angiotensin blockade with angiotensin-dependent GFR
Progressive renal insufficiency
Salvageable kidneys
Recent rise in serum creatinine
Loss of GFR during antihypertensive therapy, eg, with ACE inhibition/ARB therapy
Evidence of preserved diastolic blood flow (low resistive index; see text)
Circulatory congestion, recurrent "flash" pulmonary edema
Refractory congestive heart failure with bilateral renal arterial stenosis
ARB indicates angiotensin receptor blockade.

stood, however, that acceleration of hypertension, renal dysfunction, or target manifestations warrants reevaluation for both disease progression and/or recurrence. The optimal means for protecting kidney function and ensuring cardiovascular protection in the setting of competing risks from other medical conditions warrant careful further study.

References

- Axelrod DA, Fendrick AM, Birkmeyer JD, Wennberg DE, Siewers AE. Cardiologists performing peripheral angioplasties: impact on utilization. *Effective Clinical Practice*. 2001;4:191–198.
- Gray BH, Olin JW, Childs MB, Sullivan TM, Bacharach JM. Clinical benefit of renal artery angioplasty with stenting for the control of recurrent and refractory congestive heart failure. *Vasc Med*. 2002;7:275–279.
- Murphy TP, Soares G, Kim M. Increase in utilization of percutaneous renal artery interventions by Medicare beneficiaries 1996–2000. *Am J Roentgenol*. 2004;183:561–568.
- Plouin PF. Stable patients with atherosclerotic renal artery stenosis should be treated first with medical management: PRO. *Am J Kidney Dis*. 2003;42:851–857.
- Mailloux LU. Atherosclerotic ischemic renal vascular disease: do published outcomes justify the overzealous diagnostic approaches? *Semin Nephrol*. 2003;23:278–282.
- Cragg AH, Smith TP, Thompson BH, Maroney TP, Stanson AW, Shaw GT, Hunter DW, Cochran ST. Incidental fibromuscular dysplasia in potential renal donors: long-term clinical follow-up. *Radiology*. 1989;172:145–147.
- Neymark E, LaBerge JM, Hirose R, Melzer JS, Kerlan RK, Wilson MW, Gordon RL. Arteriographic detection of renovascular disease in potential renal donors: incidence and effect on donor surgery. *Radiology*. 2000;214:755–760.
- Slovut DP, Olin JW. Current concepts: Fibromuscular dysplasia. *N Engl J Med*. 2004;350:1862–1871.
- Tegtmeyer CJ, Selby JB, Hartwell GD, Ayers C, Tegtmeyer V. Results and complications of angioplasty in fibromuscular disease. *Circulation*. 1991;83(suppl 1):I-155–I-161.
- Krijnen P, van Jaarsveld BC, Steyerberg EW, Man in't Veld AJ, Schalekamp MADH, Habbema JKF. A clinical prediction rule for renal artery stenosis. *Ann Int Med*. 1998;129:705–711.
- Hansen KJ, Edwards MS, Craven TE, Cherr GS, Jackson SA, Appel RG, Burke GL, Dean RH. Prevalence of renovascular disease in the elderly: a population based study. *J Vasc surg*. 2002;36:443–451.
- Rihal CS, Textor SC, Breen JF, McKusick MA, Grill DE, Hallett JW, Holmes DR. Incidental renal artery stenosis among a prospective cohort of hypertensive patients undergoing coronary angiography. *Mayo Clin Proc*. 2002;77:309–316.
- Olin JW, Melia M, Young JR, Graor R, Risius B. Prevalence of atherosclerotic RAS in patients with atherosclerosis elsewhere. *Am J Med*. 1990;88:46N–51N.
- Harding MB, Smith LR, Himmelstein SI, Harrison K, Phillips HR, Schwab SJ, Hermiller JB, Davidson CJ, Bashore JM. Renal artery stenosis: prevalence and associated risk factors in patients undergoing routine cardiac catheterization. *J Am Soc Nephrol*. 1992;2:1608–1616.
- Pohl MA. Renal artery stenosis, renal vascular hypertension and ischemic nephropathy. In: Schrier RW, Gottschalk CW, eds. *Diseases of the Kidney*. Boston, Mass: Little, Brown and Co; 1997;1367–1423.
- Berglund G. Secondary hypertension in the community. In: Birkenhager WH, Reid JL, eds. *Handbook of Hypertension*. Amsterdam, Netherlands: Elsevier; 1985:249–254.
- Anderson GH, Blakemen N, Streeten DH. The effect of age on prevalence of secondary forms of hypertension in 4429 consecutively referred patients. *J Hypertens*. 1994;12:609–615.
- Textor SC, McKusick M. Renovascular hypertension and ischemic nephropathy: angioplasty and stenting. In: Brady HR, Wilcox CS, eds. *Therapy in Nephrology and Hypertension*. London, UK: WB Saunders; 2003:599–609.
- Chobanian AV, Bakris GL, Black HR, Cushman WC, Green LA, Izzo JL, Jones DW, Materson BJ, Oparil S, Wright JT, Rocella EJ, for the NHBPEP Coordinating Committee. The seventh report of the Joint National Committee on Prevention, Detection, Evaluation and Treatment of High Blood Pressure: the JNC 7 report. *JAMA*. 2003;289:2560–2572.
- Khosla S, Kunjummen B, Manda R, Khaleel R, Kular R, Gladson M, Razminia M, Guerrero M, Trivedi A, Vidyarthi V, Elbzour M, Ahmed A. Prevalence of renal artery stenosis requiring revascularization in patients initially referred for coronary angiography. *Catheter Cardiovasc Interv*. 2003;58:400–403.
- White CJ. Open renal arteries are better than closed renal arteries. *Catheter Cardiovasc Diagn*. 1998;45:9–10.
- Goldblatt H, Lynch J, Hanzal RE, Summerville WW. Studies on experimental hypertension, I: the production of persistent elevation of systolic blood pressure by means of renal ischemia. *J Exp Med*. 1934;59:347–379.
- DeForrest JM, Knappenberger RC, Antonaccio MJ, Ferrone RA, Creekmore JS. Angiotensin II is a necessary component for the development of hypertension in the two-kidney, one clip rat. *Am J Cardiol*. 1982;49:1515–1517.
- Basso N, Terragno NA. History about the discovery of the renin-angiotensin system. *Hypertension*. 2001;38:1246–1249.
- Cervenka L, Horacek V, Vaneckova I, Hubacek JA, Oliverio MI, Coffman TM, Navar LG. Essential role of AT1-A receptor in the development of 2K1C hypertension. *Hypertension*. 2002;40:735–741.
- Gavras H, Brunner HR, Vaughan ED, Laragh JH. Angiotensin-sodium interaction in blood pressure maintenance of renal hypertensive and normotensive rats. *Science*. 1973;180:1369–1370.
- Textor SC, Novick A, Mujais SK, Ross R, Bravo EL, Fouad FM, Tarazi RC. Responses of the stenosed and contralateral kidneys to (Sar-1, Thr-8) AII in human renovascular hypertension. *Hypertension*. 1983;5:796–804.
- Brunner HR, Kirshmann JD, Sealey JE, Laragh JH. Hypertension of renal origin: evidence for two different mechanisms. *Science*. 1971;174:1344–1346.
- Gavras H, Brunner HR, Thurston H, Laragh JH. Reciprocation of renin dependency with sodium-volume dependency in renal hypertension. *Science*. 1975;188:1316–1317.
- Strong CG, Hunt JC, Sheps SG, Tucker RM, Bernatz PE. Renal venous renin activity: enhancement of sensitivity of lateralization by sodium depletion. *Am J Cardiol*. 1971;27:602–611.
- Rossi GP, Cesari M, Chiesura-Corona M, Miotto D, Semplicini A, Pessina AC. Renal vein renin measurements accurately identify renovascular hypertension caused by total occlusion of the renal artery. *J Hypertens*. 2002;20:975–984.
- Kane GC, Textor SC, Schirger A, Garovic VD. Revisiting the role of nephrectomy for advanced renovascular disease. *Am J Med*. 2003;114:729–735.
- Brown JJ, Davies DL, Morton JJ, Robertson JJ, Cuesta V, Lever AF, Padfield PL. Mechanism of renal hypertension. *Lancet*. 1976;1:1219–1221.
- Lerman LO, Nath KA, Rodriguez-Porcel M, Krier JD, Schwartz RS, Napoli C. Increased oxidative stress in experimental renovascular hypertension. *Hypertension*. 2001;37:541–546.

35. Griendling KK, Fitzgerald GA. Oxidative stress and cardiovascular injury, part I: basic mechanisms and in vivo monitoring of ROS. *Circulation*. 2003;108:1912–1916.
36. Chade AR, Rodriguez-Porcel M, Grande JP, Krier JD, Lerman A, Romero JC, Napoli C, Lerman LO. Distinct renal injury in early atherosclerosis and renovascular disease. *Circulation*. 2002;106:1165–1171.
37. Ortiz M, Sanabria E, Manriquez M, Romero JC, Juncos LA. Role of endothelin and isoprostanes in the slow pressor responses to angiotensin II. *Hypertension*. 2001;37(pt 2):505–510.
38. Higashi Y, Sasaki S, Nakagawa K, Matsuura H, Oshima T, Chayama K. Endothelial function and oxidative stress in renovascular hypertension. *N Engl J Med*. 2002;346:1954–1962.
39. Parildar M, Parildar Z, Oran I, Kabaroglu C, Memis A, Bayindir O. Nitric oxide and oxidative stress in atherosclerotic renovascular hypertension: effect of endovascular treatment. *J Vasc Interv Radiol*. 2004;14:887–892.
40. Lerman A, Edwards BS, Hallett JW, Heublein DM, Sandberg SM, Burnett JC. Circulating and tissue endothelin immunoreactivity in advanced atherosclerosis. *N Engl J Med*. 1991;325:997–1001.
41. Grisk O, Rettig R. Interactions between the sympathetic nervous system and the kidneys in arterial hypertension. *Cardiovasc Res*. 2004;61:238–246.
42. Iantorno M, Pola R, Schinzari F, Filice G, Mettimano M, Cardillo C, Melina D. Association between altered circadian blood pressure profile and cardiac end-organ damage in patients with renovascular hypertension. *Cardiology*. 2003;100:114–119.
43. Ibrahim HN, Rosenberg ME, Hostetter TH. Role of the renin-angiotensin-aldosterone system in the progression of renal disease: a critical review. *Semin Nephrol*. 1997;17:431–440.
44. Epstein FH. Oxygen and renal metabolism. *Kidney Int*. 1997;51:381–385.
45. Textor SC, Wilcox CS. Renal artery stenosis: a common, treatable cause of renal failure? *Annu Rev Med*. 2001;52:421–442.
46. Cheung CM, Wright JR, Shurrab AE, Mamtara H, Foley RN, O'Donoghue DJ, Waldek S, Kalra PA. Epidemiology of renal dysfunction and patient outcome in atherosclerotic renal artery occlusion. *J Am Soc Nephrol*. 2002;13:149–157.
47. Textor SC, Novick AC, Steinmuller DR, Strem SB. Renal failure limiting antihypertensive therapy as an indication for renal revascularization. *Arch Intern Med*. 1983;143:2208–2211.
48. Grone HJ, Helmchen U. Impairment and recovery of the clipped kidney in two kidney, one clip hypertensive rats during and after antihypertensive therapy. *Lab Invest*. 1986;54:645–655.
49. Textor SC, Novick A, Tarazi RC, Klimas V, Vidt DG, Pohl M. Critical perfusion pressure for renal function in patients with bilateral atherosclerotic renal vascular disease. *Ann Intern Med*. 1985;102:309–314.
50. Chade AR, Rodriguez-Porcel M, Grande JP, Zhu X, Sica V, Napoli C, Sawamura T, Textor SC, Lerman A, Lerman LO. Mechanisms of renal structural alterations in combined hypercholesterolemia and renal artery stenosis. *Arterioscler Thromb Vasc Biol*. 2003;23:1295–1301.
51. Nath KA, Croatt AJ, Haggard JJ, Grande JP. Renal response to repetitive exposure to heme proteins: chronic injury induced by an acute insult. *Kidney Int*. 2000;57:2423–2433.
52. Textor SC. Ischemic nephropathy: where are we now? *J Am Soc Nephrol*. 2004;15:1974–1982.
53. Simon N, Franklin SS, Bleifer KH, Maxwell MH. Clinical characteristics of renovascular hypertension. *JAMA*. 1972;220:1209–1218.
54. Atkinson AB, Davies DL, Leckie B, Morton JJ, Borwn JJ, Fraser R, Lever AF, Robertson JI. Hyponatremic hypertensive syndrome with renal artery occlusion corrected by captopril. *Lancet*. 1979;2:606–609.
55. Mounier-Vehier C, Cochetoux B, Haulon S, Devos P, Lions C, Gautier C, Carre A, Beregi JP. Changes in renal blood flow reserve after angioplasty of renal artery stenosis in hypertensive patients. *Kidney Int*. 2004;65:245–250.
56. Ruggenti P, Mosconi L, Bruno S, Remuzzi A, Sangalli F, Lepre MS, Agazzi R, Nani R, Fasolini G, Remuzzi G. Post-transplant renal artery stenosis: the hemodynamic response to revascularization. *Kidney Int*. 2001;60:309–318.
57. van de Ven PJG, Beutler JJ, Kaatee R, Beek FJA, Mali WPTM, Koornans HA. Angiotensin converting enzyme inhibitor-induced renal dysfunction in atherosclerotic renovascular disease. *Kidney Int*. 1998;53:986–993.
58. Holm EA, Randlov A, Strandgaard S. Brief Report: acute renal failure after losartan treatment in a patient with bilateral renal artery stenosis. *Blood Pressure*. 1996;5:360–362.
59. Schoolwerth AC, Sica DA, Ballermann BJ, Wilcox CS. Renal considerations in angiotensin converting enzyme inhibitor therapy. *Circulation*. 2001;104:1985–1991.
60. Jackson B, Matthews PG, McGrath BP, Johnston CI. Angiotensin converting enzyme inhibition in renovascular hypertension: frequency of reversible renal failure. *Lancet*. 1984;i:225–226.
61. Kennedy DJ, Colyer WR, Brewster PS, Ankenbrandt M, Burket MW, Nemeth AS, Khuder SA, Thomas WJ, Shapiro JI, Cooper CJ. Renal insufficiency as a predictor of adverse events and mortality after renal artery stent placement. *Am J Kidney Dis*. 2003;14:926–935.
62. Gandhi SK, Powers JC, Nomeir AM, Fowle K, Kitzman DW, Rankin KM, Little WC. The pathogenesis of acute pulmonary edema associated with hypertension. *N Engl J Med*. 2001;344:17–22.
63. Bloch MJ, Trost DW, Pickering TG, Sos TA, August P. Prevention of recurrent pulmonary edema in patients with bilateral renovascular disease through renal artery stent placement. *Am J Hyper*. 1999;12:1–7.
64. MacDowall P, Kalra PA, O'Donoghue DJ, Mamtara H, Waldek S, Brown K. Risk of morbidity from renovascular disease in elderly patients with congestive cardiac failure. *Lancet*. 1998;352:13–16.
65. Wilcox CS. Use of angiotensin converting enzyme inhibitors for diagnosing renovascular hypertension. *Kidney Int*. 1993;44:1379–1390.
66. Sfakianakis GN, Bourgoignie JJ. Renographic diagnosis of renovascular hypertension with angiotensin converting enzyme inhibition and furosemide. *Am J Hyper*. 1991;4:706s–710s.
67. Novick AC, Fouad FM, Textor SC, Bravo EL, Tarazi RC, Gifford RW, Vidt DG. Predictive value of angiotensin II blockade with (sarcoisine-1-threonine-8) angiotensin II in renovascular hypertension. *J Urol*. 1983;129:7–10.
68. Postma CT, van Oijen AH, Barentsz JO, de Boo T, Hoefnagels WH, Corstens FH, Thien T. The value of tests predicting renovascular hypertension in patients with renal artery stenosis treated by angioplasty. *Arch Intern Med*. 1991;151:1531–1535.
69. Textor SC. Pitfalls in imaging for renal artery stenosis. *Ann Intern Med*. 2004;141:730–731.
70. Postma CT, Joosten FB, Rosenbusch G, Thien T. Magnetic resonance angiography has a high reliability in the detection of renal artery stenosis. *Am J Hypertens*. 1997;10:957–963.
71. Leung DA, Hagspiel KD, Angle JF, Spinoza DJ, Matsumoto AH, Butty S. MR angiography of the renal arteries. *Radiol Clin North Am*. 2002;40:847–865.
72. Vasbinder GBC, Nelemans PJ, Kessels AGH, Kroon AA, Maki JH, Leiner T, Beek FJA, Korst MBJM, Flobbe K, de Haan MW, van Zwam WH, Postma CT, Hunink M, de Leeuw PW, van Engelshoven JMA. Accuracy of computed tomographic angiography and magnetic resonance angiography for diagnosing renal artery stenosis. *Ann Intern Med*. 2004;141:674–682.
73. Radermacher J, Weinkove R, Haller H. Techniques for predicting favourable response to renal angioplasty in patients with renovascular disease. *Curr Opin Nephrol Hypertens*. 2002;10:799–805.
74. Radermacher J, Chavan A, Bleck J, Vitzthum A, Stoess B, Gebel MJ, Galanski M, Koch KM, Haller H. Use of Doppler ultrasonography to predict the outcome of therapy for renal-artery stenosis. *N Engl J Med*. 2001;344:410–417.
75. Forbes JM, Hewitson TD, Becker GJ, Jones CL. Simultaneous blockade of endothelin A and B receptors in ischemic acute renal failure is detrimental to long-term kidney function. *Kidney Int*. 2001;59:1333–1341.
76. Juknevicius I, Segal Y, Kren S, Lee R, Hostetter TH. Effect of aldosterone on renal transforming growth factor- β . *Am J Physiol Renal Fluid Electrolyte Physiol*. 2004;286:F1059–F1062.
77. Border WA, Noble NA. Interactions of transforming growth factor-beta and angiotensin II in renal fibrosis. *Hypertension*. 1998;31(pt 2):181–188.
78. Tomita H, Egashira K, Ohara Y, Takemoto M, Koyanagi M, Katoh M, Yamamoto H, Tamaki K, Shimokawa H, Takeshita A. Early induction of transforming growth factor- β via angiotensin II type 1 receptors contributes to cardiac fibrosis induced by long-term blockade of nitric oxide synthesis in rats. *Hypertension*. 1998;32:273–279.
79. Schnee JM, Hsueh WA. Angiotensin II, adhesion, and cardiac fibrosis. *Cardiovasc Res*. 2000;46:264–268.

80. Losito A, Gaburri M, Errico R, Parente B, Cao PG. Survival of patients with renovascular disease and ACE inhibition. *Clin Nephrol*. 1999;52:339–343.
81. Chabova V, Schirger A, Stanson AW, McKusick M, Textor SC. Outcomes of atherosclerotic renal artery stenosis managed without revascularization. *Mayo Clin Proc*. 2000;75:437–444.
82. Dorros G, Jaff M, Mathiak L, He T. Multicenter registry participants. Multicenter Palmaz stent renal artery stenosis revascularization registry report: four-year follow-up of 1,058 successful patients. *Catheter Cardiovasc Interv*. 2002;55:182–188.
83. Uzzo RG, Novick AC, Goormastic M, Mascha E, Pohl M. Medical versus surgical management of atherosclerotic renal artery stenosis. *Transplant Proc*. 2002;34:723–725.
84. Taler SJ, Textor SC, Augustine JE. Resistant hypertension: comparing hemodynamic management to specialist care. *Hypertension*. 2002;39:982–988.
85. Dorros G, Jaff M, Mathiak L, Dorros I, Lowe A, Murphy K, He T. Four-year follow-up of Palmaz-Schatz stent revascularization as treatment for atherosclerotic renal artery stenosis. *Circulation*. 1998;98:642–647.
86. Hollenberg NK. Medical therapy for renovascular hypertension: a review. *Am J Hypertens*. 1988;1:338s–343s.
87. Franklin SS, Smith RD. Comparison of effects of enalapril plus hydrochlorothiazide versus standard triple therapy on renal function in renovascular hypertension. *Am J Med*. 1985;79(suppl 3c):14–23.
88. Hricik DE, Browning PJ, Kopelman R, Madias NE, Dzau VJ. Captopril-induced functional renal insufficiency in patients with bilateral renal artery stenosis or renal artery stenosis in a solitary kidney. *N Engl J Med*. 1983;308:373–376.
89. Zimmerman BG. Renal vascular reactivity to U46619 and adrenergic agonists in Goldblatt hypertension. *Am J Physiol*. 1987;253:H1523–H1529.
90. Veniant M, Heudes D, Clozel JP, Bruneval P, Menard J. Calcium blockade versus ACE inhibition in clipped and unclipped kidneys of 2K-1C rats. *Kidney Int*. 1994;46:421–429.
91. Devoy MA, Tomson CR, Edmunds ME, Feehally J, Walls J. Deterioration in renal function associated with angiotensin converting enzyme inhibitor therapy is not always reversible. *J Intern Med*. 1992;232:493–498.
92. Wenting GJ, Derkx FH, Tan-Tjong LH, van Seyen AJ, Man in't Veld AJ, Schalekamp MA. Risks of angiotensin converting enzyme inhibition in renal artery stenosis. *Kidney Int*. 1987;20(suppl):S180–S183.
93. Hollenberg NK. Medical therapy of renovascular hypertension: efficacy and safety of captopril in 269 patients. *Cardiovasc Rev Rep*. 1983;4:852–876.
94. Textor SC. Renal failure related to ACE inhibitors. *Semin Nephrol*. 1997;17:67–76.
95. Oster JR, Materson BJ. Renal and electrolyte complications of congestive heart failure and effects of therapy with angiotensin-converting enzyme inhibitors. *Arch Int Med*. 1992;152:704–710.
96. Hricik DE. Captopril-induced renal insufficiency and the role of sodium balance. *Ann Intern Med*. 1985;103:222–223.
97. Patrono C, Dunn MJ. The clinical significance of inhibition of renal prostaglandin synthesis. *Kidney Int*. 1987;32:1–12.
98. Stanley JC. Surgical treatment of renovascular hypertension. *Am J Surg*. 1997;174:102–110.
99. Martinez AG, Novick AC, Hayes JM. Surgical treatment of renal artery stenosis after failed percutaneous transluminal angioplasty. *J Urol*. 1990;144:1094–1096.
100. van de Ven PJ, Kaatee R, Beutler JJ, Beek FJ, Woittiez AJ, Buskens E, Koomans HA, Mali WP. Arterial stenting and balloon angioplasty in ostial atherosclerotic renovascular disease: a randomised trial. *Lancet*. 1999;353:282–286.
101. Bloch MJ, Pickering T. Renal vascular disease: medical management, angioplasty and stenting. *Semin Nephrol*. 2000;20:474–488.
102. Ramsay LE, Waller PC. Blood pressure response to percutaneous transluminal angioplasty for renovascular hypertension: an overview of published series. *BMJ*. 1990;300:569–572.
103. Isles CG, Robertson S, Hill D. Management of renovascular disease: a review of renal artery stenting in ten studies. *Q J Med*. 1999;92:159–167.
104. Webster J, Marshall F, Abdalla M, Dominiczak A, Edwards R, Isles CG, Loose H, Main J, Padfield P, Russell IT, Walker B, Watson M. Randomised comparison of percutaneous angioplasty vs continued medical therapy for hypertensive patients with atherosclerotic renal artery stenosis. *J Hum Hypertens*. 1998;12:329–335.
105. van Jaarsveld BC, Krijnen P, Pieterman H, Derkx FHM, Deinum J, Postma CT, Dees A, Woittiez AJ, Bartelink AKM, Man in't Veld AJ, Schalekamp MADH, for the Dutch Renal Artery Stenosis Intervention Cooperative Study Group. The effect of balloon angioplasty on hypertension in atherosclerotic renal-artery stenosis. *N Engl J Med*. 2000;342:1007–1014.
106. Plouin PF, Chatellier G, Darne B, Raynaud A. Blood pressure outcome of angioplasty in atherosclerotic renal artery stenosis: a randomized trial. *Hypertension*. 1998;31:822–829.
107. Nordmann AJ, Woo K, Parkes R, Logan AG. Balloon angioplasty or medical therapy for hypertensive patients with atherosclerotic renal artery stenosis? A meta-analysis of randomized controlled trials. *Am J Med*. 2003;114:44–50.
108. Ives NJ, Wheatley K, Stowe RL, Krijnen P, Plouin PF, van Jaarsveld BC, Gray R. Continuing uncertainty about the value of percutaneous revascularization in atherosclerotic renovascular disease: a meta-analysis of randomized trials. *Nephrol Dial Transplant*. 2003;18:298–304.
109. Gill KS, Fowler RC. Atherosclerotic renal arterial stenosis: clinical outcomes of stent placement for hypertension and renal failure. *Radiology*. 2003;226:821–826.
110. Rimmer JM, Gennari FJ. Atherosclerotic renovascular disease and progressive renal failure. *Ann Intern Med*. 1993;118:712–719.
111. Messina LM, Zelenock GB, Yao KA, Stanley JC. Renal revascularization for recurrent pulmonary edema in patients with poorly controlled hypertension and renal insufficiency: a distinct subgroup of patients with arteriosclerotic renal artery occlusive disease. *J Vasc Surg*. 1992;15:73–82.
112. Pickering TG, Herman L, Devereux RB, Sotelo JE, James GD, Sos TA, Silane MF, Laragh JH. Recurrent pulmonary oedema in hypertension due to bilateral renal artery stenosis: treatment by angioplasty or surgical revascularisation. *Lancet*. 1988;2:551–552.
113. Maurea S, Klain M, Caraco C, Ziviello M, Salvatore M. Diagnostic accuracy of radionuclide imaging using 131-I nor-cholesterol or metaiodobenzylguanidine in patients with hypersecreting or non-hypersecreting adrenal tumours. *Nucl Med Commun*. 2002;23:951–960.
114. Ivanovic V, McKusick MA, Johnson CM, Sabater EA, Andrews JC, Breen JF, Bjarnason H, Misra S, Stanson AW. Renal artery stent placement: complications at a single tertiary care center. *J Vasc Intervent Radiol*. 2003;14:217–225.
115. Collins R, Yusuf S, Peto R. Overview of randomised trials of diuretics in pregnancy. *BMJ (Clin Res Ed)*. 1985;290:17–23.
116. Conlon PJ, Athirakul K, Kovalik E, Schwab SJ, Crowley J, Stack R, McCants CB, Mark DB, Bashore TM, Albers F. Survival in renal vascular disease. *J Am Soc Nephrol*. 1998;9:252–256.
117. Textor SC. Progressive hypertension in a patient with “incidental” renal artery stenosis. *Hypertension*. 2002;40:595–600.
118. Textor SC. Renovascular hypertension and ischemic nephropathy. In: Brenner BM, ed. *Brenner and Rector's: The Kidney*. Philadelphia, Pa: Saunders; 2004: 2065–2108.

KEY WORDS: hypertension, renal ■ hypertension, renovascular ■ kidney ■ revascularization ■ stents

Renovascular Hypertension and Ischemic Nephropathy

Vesna D. Garovic and Stephen C. Textor

Circulation. 2005;112:1362-1374

doi: 10.1161/CIRCULATIONAHA.104.492348

Circulation is published by the American Heart Association, 7272 Greenville Avenue, Dallas, TX 75231

Copyright © 2005 American Heart Association, Inc. All rights reserved.

Print ISSN: 0009-7322. Online ISSN: 1524-4539

The online version of this article, along with updated information and services, is located on the
World Wide Web at:

<http://circ.ahajournals.org/content/112/9/1362>

Permissions: Requests for permissions to reproduce figures, tables, or portions of articles originally published in *Circulation* can be obtained via RightsLink, a service of the Copyright Clearance Center, not the Editorial Office. Once the online version of the published article for which permission is being requested is located, click Request Permissions in the middle column of the Web page under Services. Further information about this process is available in the [Permissions and Rights Question and Answer](#) document.

Reprints: Information about reprints can be found online at:
<http://www.lww.com/reprints>

Subscriptions: Information about subscribing to *Circulation* is online at:
<http://circ.ahajournals.org/subscriptions/>